Κρυπτογενής Οργανούμενη Πνευμονία

Cryptogenic organizing pneumonia (OP- COP- BOOP)

Δανιήλ Ζωή
Επίκουρος Καθηγήτρια Πνευμονολογίας
Πνευμονολογική Κλινική
Ιατρική Σχολή Πανεπιστημίου Θεσσαλίας

Κατερίνα Αντωνίου
Λέκτορας Πνευμονολογίας
Ιατρική Σχολή Πανεπιστημίου Κρήτης

BOOP (COP)
Κατάταξη των διάμεσων παρεγχυματικών νοσημάτων πνεύμονα

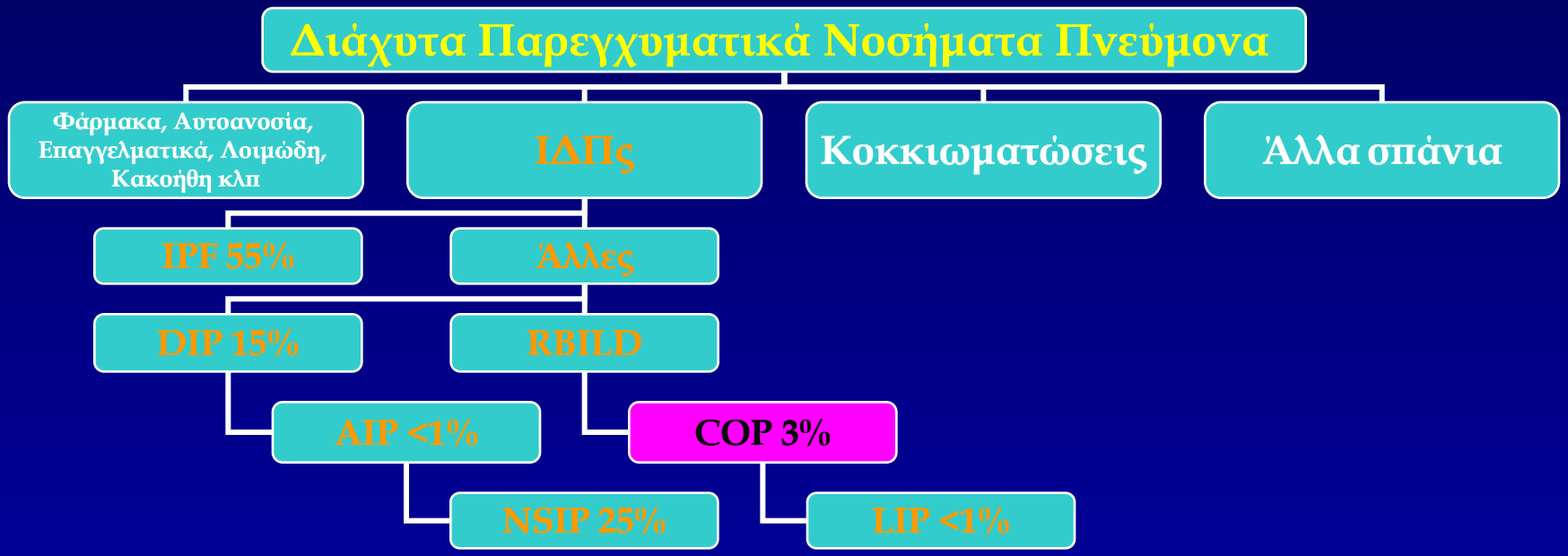

ATS/ERS Consensus classification of the IIPs AJRCCM 2002; 165: 277-304

Ορισμός

Organising pneumonia is defined ***histopathologically*** by intra-alveolar buds of granulation tissue, consisting of intermixed myofibroblasts and connective tissue. Although nonspecific, this histopathological pattern, together with characteristic clinical and imaging features, defines cryptogenic organising pneumonia when no cause or peculiar underlying context is found. Rapid clinical and imaging improvement is obtained with corticosteroid treatment, but relapses are common after stopping treatment.

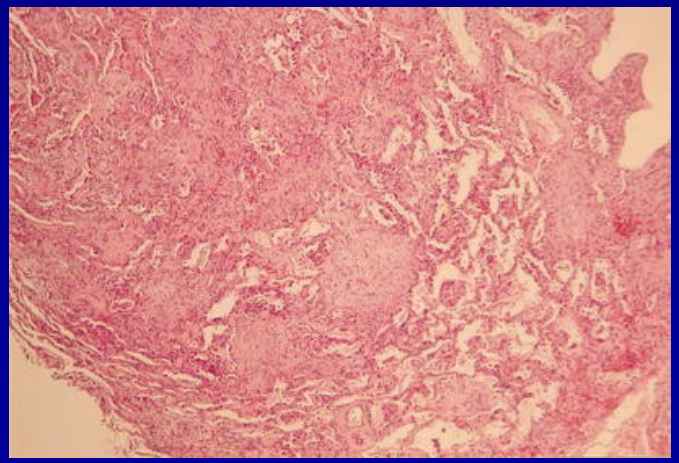

Cordier J-F, Eur Respir J 2006

OP- COP- BOOP

- Organizing pneumonia of determined cause
- Organizing pneumonia of undetermined cause but occurring in a specific and relevant context
- Cryptogenic (idiopathic) organizing pneumonia

Nomenclature change because:

- 1. From the histological point of view, although the bronchiolitis obliterans OP (which suggests obstructive histological changes of the small airways) may coexist with OP, is not always the case.
- 2. restrictive pattern in OP in contrast to an obstructive pattern in bronchiolitis.

Infectious causes of organising pneumonia

Organism
Bacteria
Burkholderia cepacia
Chlamydia pneumoniae
Coxiella burnetii
Legionella pneumophila
Mycoplasma pneumoniae
Nocardia asteroides
Pseudomonas aeruginosa
Serratia marcescens
Staphylococcus aureus
Streptococcus pneumoniae
Viruses
Adenovirus
Cytomegalovirus
Herpes virus
HIV
Influenza virus
Parainfluenza virus
Human herpes virus-7
Respiratory syncytial virus
Parasites
Plasmodium vivax
Dirofilaria immitis
Fungi
Cryptococcus neoformans
Penicillium janthinellum
Pneumocystis jiroveci

Cordier J-F, Eur Respir J 2006

Drugs identified as a cause of organising pneumonia

Drug
5-Aminosalicylic acid
Acebutolol
Amiodarone
Amphotericin B
Bleomycin
Busulfan
Busulfan and cyclophosphamide
Carbamazepine
Cephalosporin (cefradin)
Chlorambucil
Doxorubicin
Fluvastatin
Gold salts
Hexamethonium
Interferon-α
Interferon-α2b, pegylated interferon α2b
Interferon-α + cytosine arabinoside
Interferon + ribavirin
Interferon-β1a
L-tryptophan
Mesalazine
Methotrexate
Minocycline
Nilutamide
Nitrofurantoin
Phenytoin
Sirolimus
Sotalol
Sulfasalazine
Tacrolimus
Ticlopidine
Trastuzumab
Vinbarbital-aprobarbital

Cordier J-F, Eur Respir J 2006

Connective tissue disorders

– Systemic lupus erythematosus [38]
– Rheumatoid arthritis [39]
– Sjogren syndrome [40]
– Polymyositis [40]
– Dermatomyositis [41]
– Polymyalgia rheumatica [42]

Immunological disorders

– Common variable immunodeficiency syndrome [43]
– Essential mixed cryoglobulinaemia [44]

Organ transplantation

– Bone marrow [45]
– Lung [46]
– Renal [47]

Miscellaneous

– Inflammatory bowel disease [48]
– Primary biliary cirrhosis [49]
– Polyarteritis nodosa [50]
– Haematological malignancies
– Myelodysplastic syndrome [51]
– T-cell leukaemia [52]
– Lymphoma [53]
– Seasonal syndrome with cholestasis [54]
– Radiotherapy [55, 56]
– Environmental exposure (textile printing dye) [57]
– Penicillium mould dust [58]

The “typical” COP syndrome

- Flu-like illness accompanied with:

  fever, non-productive cough, malaise, anorexia and weight loss.

- Dyspnoea is common but usually mild and evident only on exertion.

- Less common symptoms are bronchorrhoea, haemoptysis (but severe haemoptysis is exceedingly rare), chest pain, arthralgia and night sweats.

BOOP Επιδημιολογικά δεδομένα

- 6-7 ασθενείς /100.000 εισαγωγές σε μεγάλα νοσοκομεία
- Μη καπνιστές / καπνιστές: 2 / 1
- Ομοιόμορφη κατανομή ανάμεσα στα 2 φύλα
- Μέση ηλικία εμφάνισης 55 έτη

Alasaly K, et al. Medicine 1995; 74: 201-211

Laboratory Findings



- Routine laboratory studies are nonspecific
- Leukocytosis is present in about 50 percent of patients
- Elevated initial ESR (frequently reaching or exceeding 100 mm)
- Positive C-reactive protein are observed in 70 to 80 percent
- Autoantibodies are usually negative or present in very low titer
- *An increase of -glutamate transferase and alkaline phosphatase may be associated with multiple relapses.*

Chest radiograph

- Peripheral distribution of the opacities, similar to that seen in CEP.
- The consolidative and GGO are rarely unilateral
- Recurrent or migratory pulmonary opacities are common (>50%)
- Irregular linear or nodular opacities are rarely present as the only manifestation
- Honeycombing is rare
- Other: pleural effusion, pleural thickening,hyperinflation and cavities

Organizing Pneumonia

FOTIS DRAKOPANAGIOTAKIS, MD; VLASIS POLYCHRONOPOULOS, MD; MARC A. JUDSON, MD

Am J Med Sci 2008

3 radiological patterns/clinical presentation

- ***This pattern is often confused with infectious pneumonia.***

- These opacities are usually located in the lower lung lobes, and they may be recurrent and migratory in up to 50% of the cases.

- HRCT detects such abnormalities in more than 90% of cases. Their density ranges from consolidation to ground-glass opacities.

- Air bronchograms and bronchial dilatation are often observed.

Figure 2. Typical chest radiograph with OP showing a localized alveolar opacity suggesting infectious pneumonia.

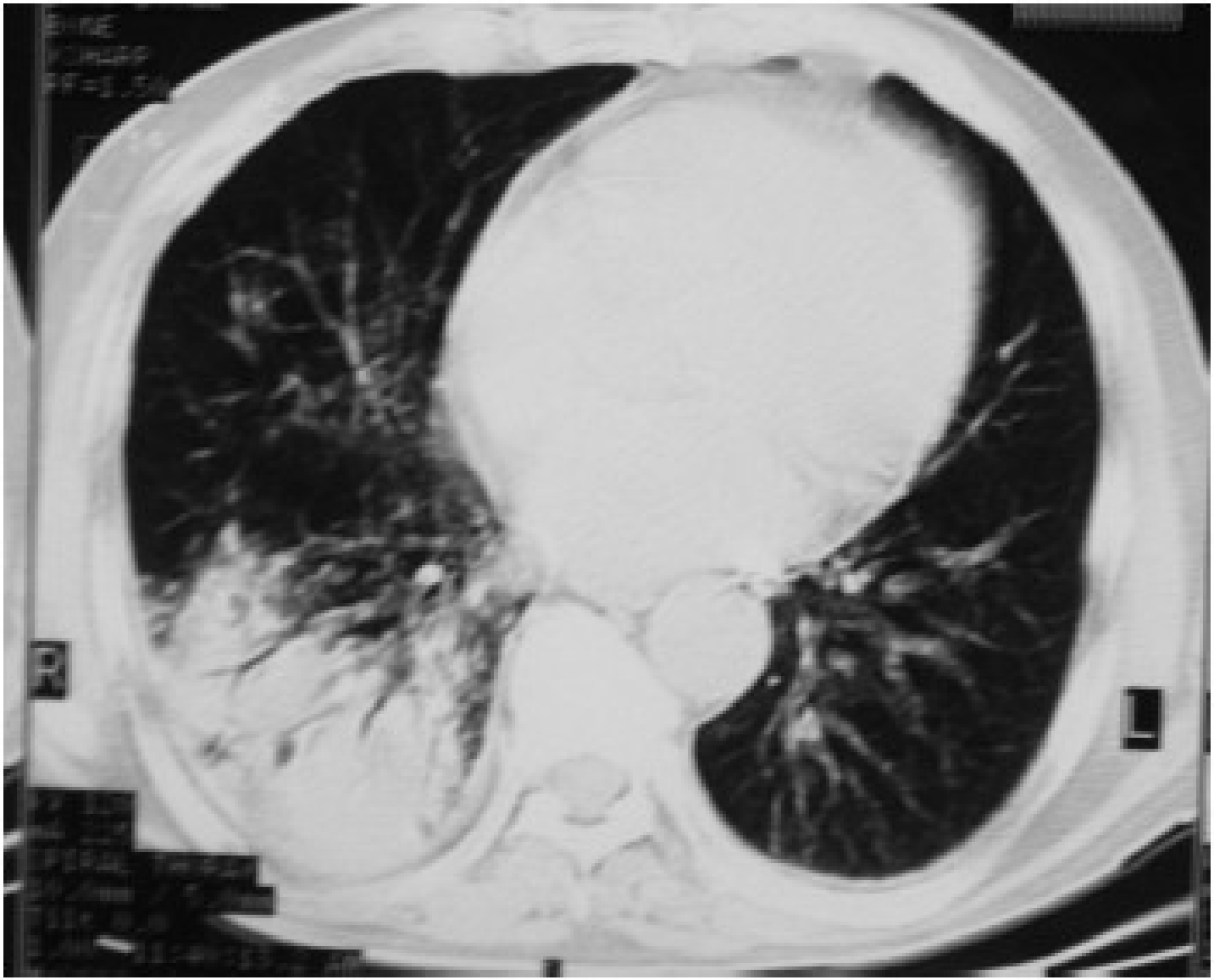

Figure 3. Organizing pneumonia presenting as right lower lobe alveolar opacities.

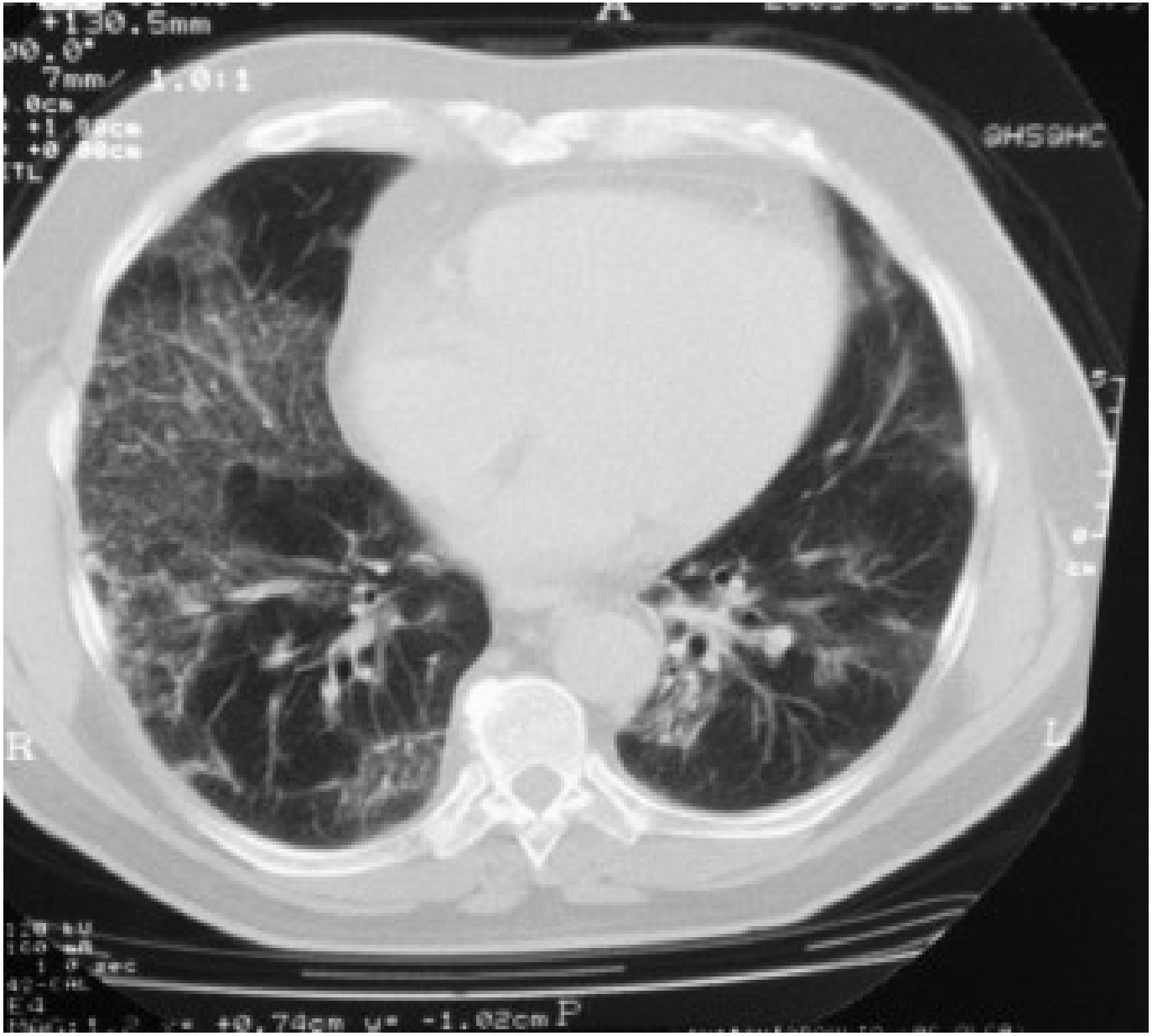

Figure 4. Ground-glass radiological appearance of OP.

- The second radiological pattern is a solitary pulmonary nodule (10% to 15% of patients).
- These lesions may occasionally cavitate.
- Patients with this radiologic pattern may have the clinical syndrome of OP or be asymptomatic.

- ***The diagnosis usually requires surgical excision of the lesion, since, even if transbronchial biopsy specimens show organizing pneumonia, this is inadequate to exclude an adjacent peripheral lung cancer.***

CT features have been proposed to be helpful in suggesting the nodular pattern of OP rather than lung cancer:

- a) location of the lesion in contact with the pleura (ie, relatively broad pleural based lesion) or along the bronchovascular bundle with some contraction and convergence of vessels;
- b) the presence of flat, oval, or trapezoidal-shaped masses instead of a rounded lesion;
- c) the presence of satellite lesions.

Third pattern

- infiltrative lung disease (less than 10% of the patients)
- This pattern consists of reticular opacities

and superimposed alveolar opacities.

- It probably represents an overlap of OP with other interstitial pneumonias.
- These patterns usually present with progressive dyspnea

Pulmonary function tests

- A mild to moderate restrictive ventilatory defect is most common.
- The pressure-volume curve is shifted downward and to the right, consistent with a stiff, noncompliant lung.
- The diffusing capacity (DLCO) is reduced in the majority of patients.
- Resting and/or exercise arterial hypoxemia are present in more than 80 percent of subjects

TABLE 25–21 CT Patterns in Organizing Pneumonia

CT Pattern	*CT Features*
Classic COP pattern	Bilateral patchy air-space consolidation Volume loss may be present
Focal pattern	Focal solitary organizing pneumonia Commonly found in upper lobes
Nodular pattern	Acinar pattern with nodules ~8 mm in diameter Subtle poorly defined (micro)nodular pattern Multiple large nodules or masses
Bronchocentric pattern	Areas of consolidation surrounding bronchovascular bundles Appears commonly in patients with polymyositis and dermatomyositis
Linear and band-like pattern	Lines or bands > 2 cm, smooth or irregular sometimes forming arcades and/or containing air bronchograms. Usually at least 8 mm in width. They are rarely the only finding. Some extend in a radial manner along the line of the bronchi towards the pleura, usually intimately related to bronchi Some occur in a peripheral location bearing no relationship to the bronchi
Perilobular pattern	Localization of parenchymal disease at the level of the secondary pulmonary lobule Usually associated with areas of consolidation or near nodules and masses
Progressive fibrotic pattern	Bibasal reticular pattern may be superimposed on a background of areas of frank consolidation or acinar nodules Most frequently seen with connective tissue diseases; carries a poorer prognosis

Cryptogenic Organizing Pneumonia: Serial High-Resolution CT Findings in 22 Patients

AJR

TABLE 2: Initial and Follow-Up CT Patterns, Distribution, and Extent of Lung Involvement in 22 Patients With Cryptogenic Organizing Pneumonia

Parameter	Initial CT		Follow-Up CT	
	No. (%) of Patients	Average Extent (%)	No. (%) of Patients	Average Extent (%)
Pattern				
Consolidation	17 (77)	27	1 (5)	20
Ground-glass opacification	19 (86)	33	16 (72)	21
Nodule	7 (32)	10	1 (5)	10
Reticulation	4 (18)	10	11 (50)	12
Honeycombing	0	0	2 (9)	8
Distribution				
Lower lung predominance	12 (55)	NA	10 (45)	NA
Subpleural	9 (41)	NA	8 (36)	NA
Peribronchovascular	5 (23)	NA	4 (18)	NA

Note— NA = not applicable.

Lee, J. W. et al. Am. J. Roentgenol. 2010;195:916-922

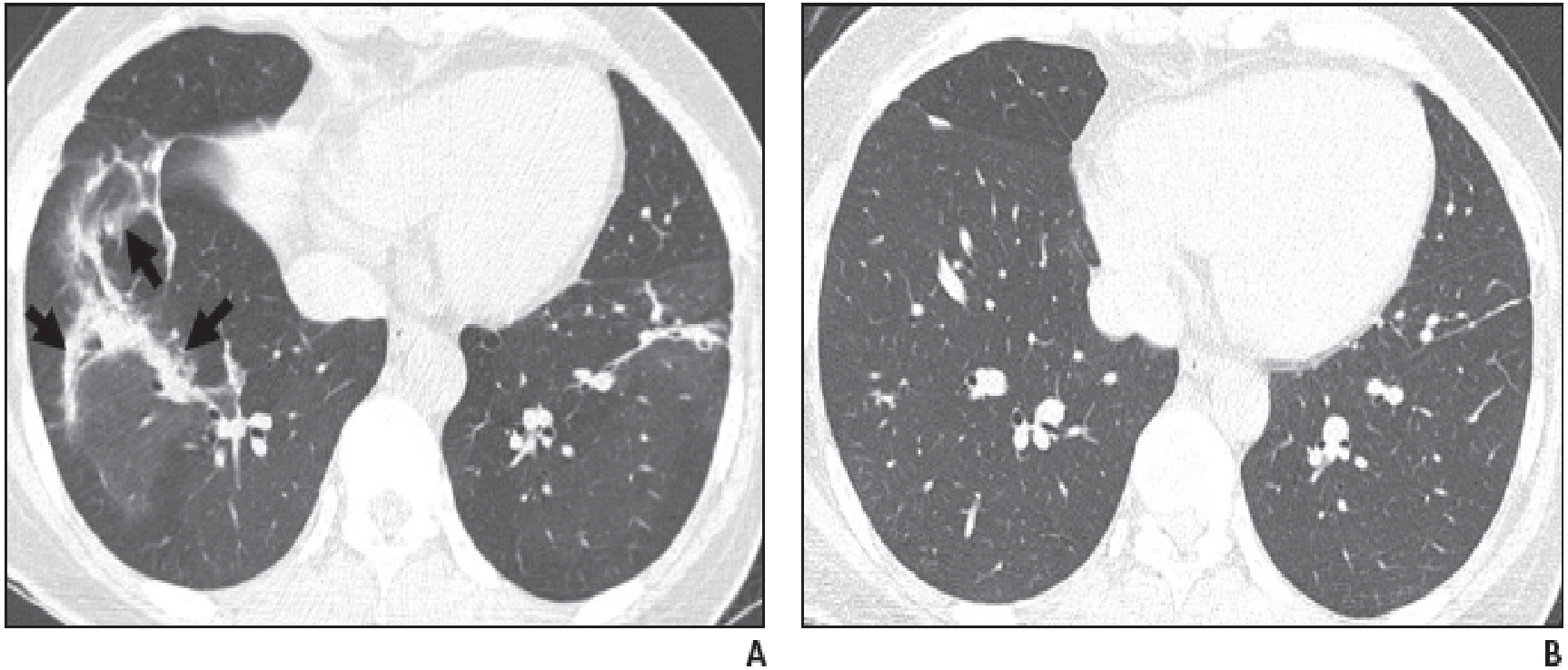

Fig. 1—43-year-old woman with cryptogenic organizing pneumonia showing complete resolution on follow-up CT scans.
A, Transverse thin-section (1.0-mm section thickness) CT scan obtained at level of basal segmental bronchi shows bilateral patchy ground-glass opacification (GGO) lesions distributed along bronchovascular bundles in lower lung zones. Linear consolidation surrounds internal GGO, so-called "reversed halo sign" (*arrows*), in right lower lobe. There was no parenchymal opacity in upper and middle lung zones (not shown here). Total extent of parenchymal abnormalities on CT scans was 20% (consolidation, 10%; GGO, 10%).
B, Nine-month follow-up CT scan obtained at similar level to panel **A** shows complete resolution of lung lesions without remaining disease.

Lee, J. W. et al. Am. J. Roentgenol. 2010;195:916-922

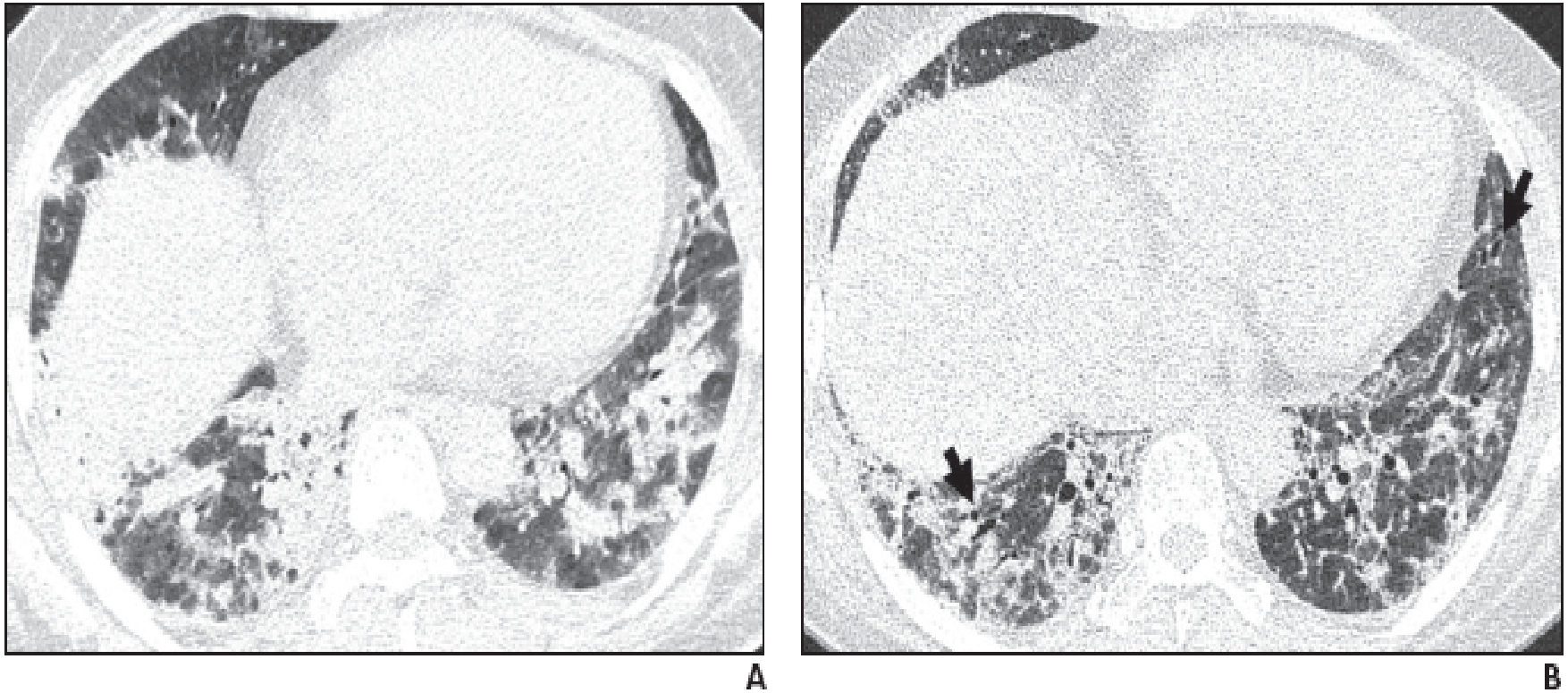

Fig. 2—56-year-old woman with cryptogenic organizing pneumonia showing improvement but remaining disease.
A, Transverse thin-section (1.0-mm section thickness) CT scan obtained at level of liver dome shows bilateral patchy areas of consolidation and nodules distributed along bronchovascular bundles in lower lung zones. Total extent of parenchymal abnormalities on CT scans was 50% (consolidation, 40%; nodule, 10%).
B, Nine-month follow-up CT scan obtained at similar level to panel A shows decreased extent of parenchymal lesions. Total extent of remaining lung lesions was 30% (ground-glass opacification, 20%; reticulation, 10%). Note associated traction bronchiectasis (*arrows*) in both lower lobes. Remaining abnormalities are suggestive of fibrotic nonspecific interstitial pneumonia.

Lee, J. W. et al. Am. J. Roentgenol. 2010;195:916-922

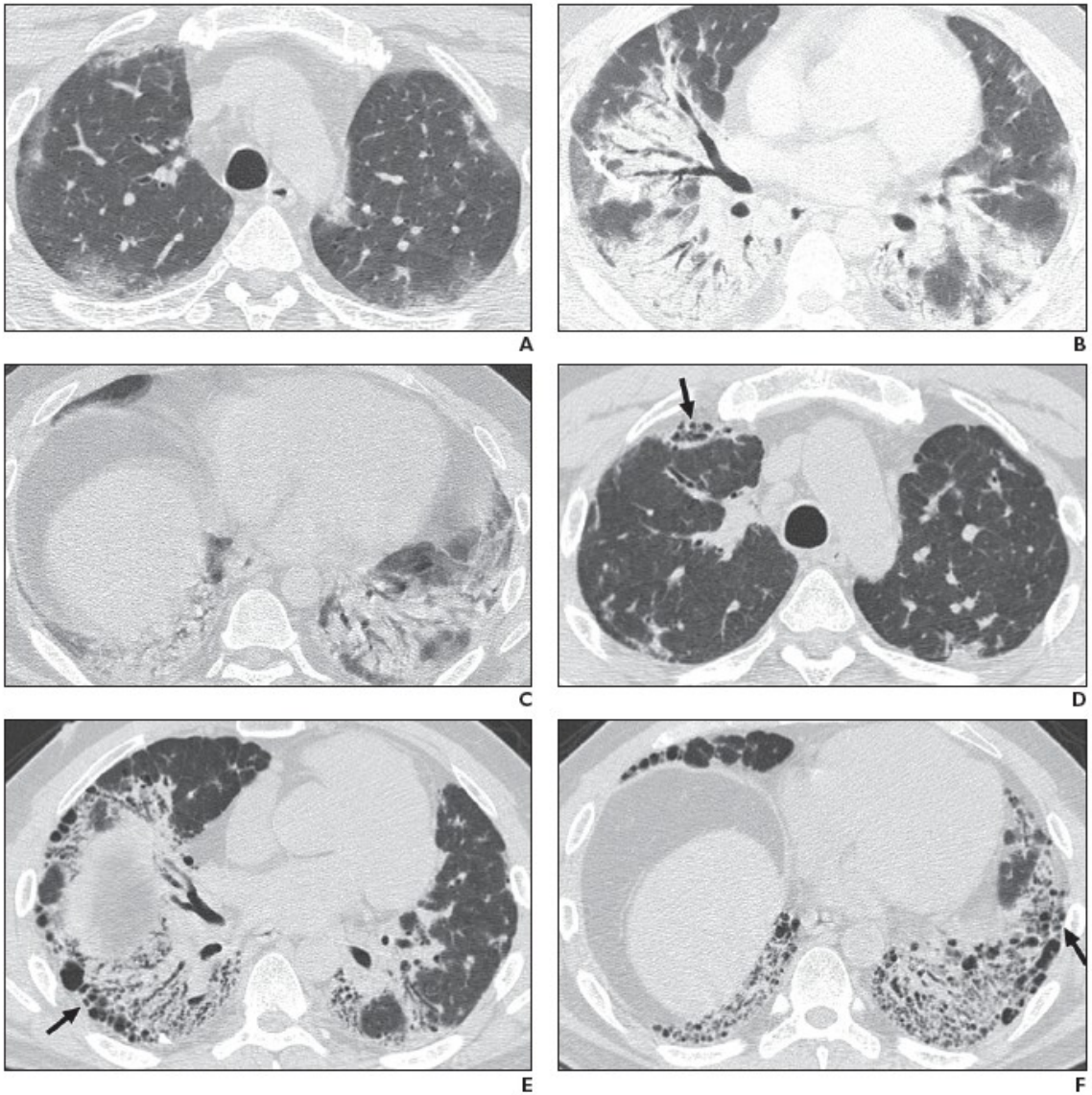

Fig. 3—35-year-old man with cryptogenic organizing pneumonia showing decrease in total extent of disease (improvement) but remaining disease.
A–C, Transverse thin-section (1.0-mm section thickness) CT scans obtained at levels of trachea (**A**), superior segmental bronchi of lower lobes (**B**), and liver dome (**C**), respectively, show bilateral consolidation, ground-glass opacification (GGO), and nodules of lower lung zone and subpleural distribution. Total extent of parenchymal abnormalities on CT scans were 70% (consolidation, 40%; GGO, 20%; nodules, 10%).
D–F, Follow-up CT scans (135 months) obtained at similar levels to panels **A**, **B**, and **C**, respectively, show decreased extent of parenchymal lesions. Total extent of remaining lesions was 40% (GGO, 20%; reticulation, 10%; honeycombing [*arrows*], 10%). Remaining abnormalities show subpleural and lower lung zone predominance and simulate usual interstitial pneumonia pattern.

Lee, J. W. et al. Am. J. Roentgenol. 2010;195:916-922

Organizing pneumonia:
the many morphological faces

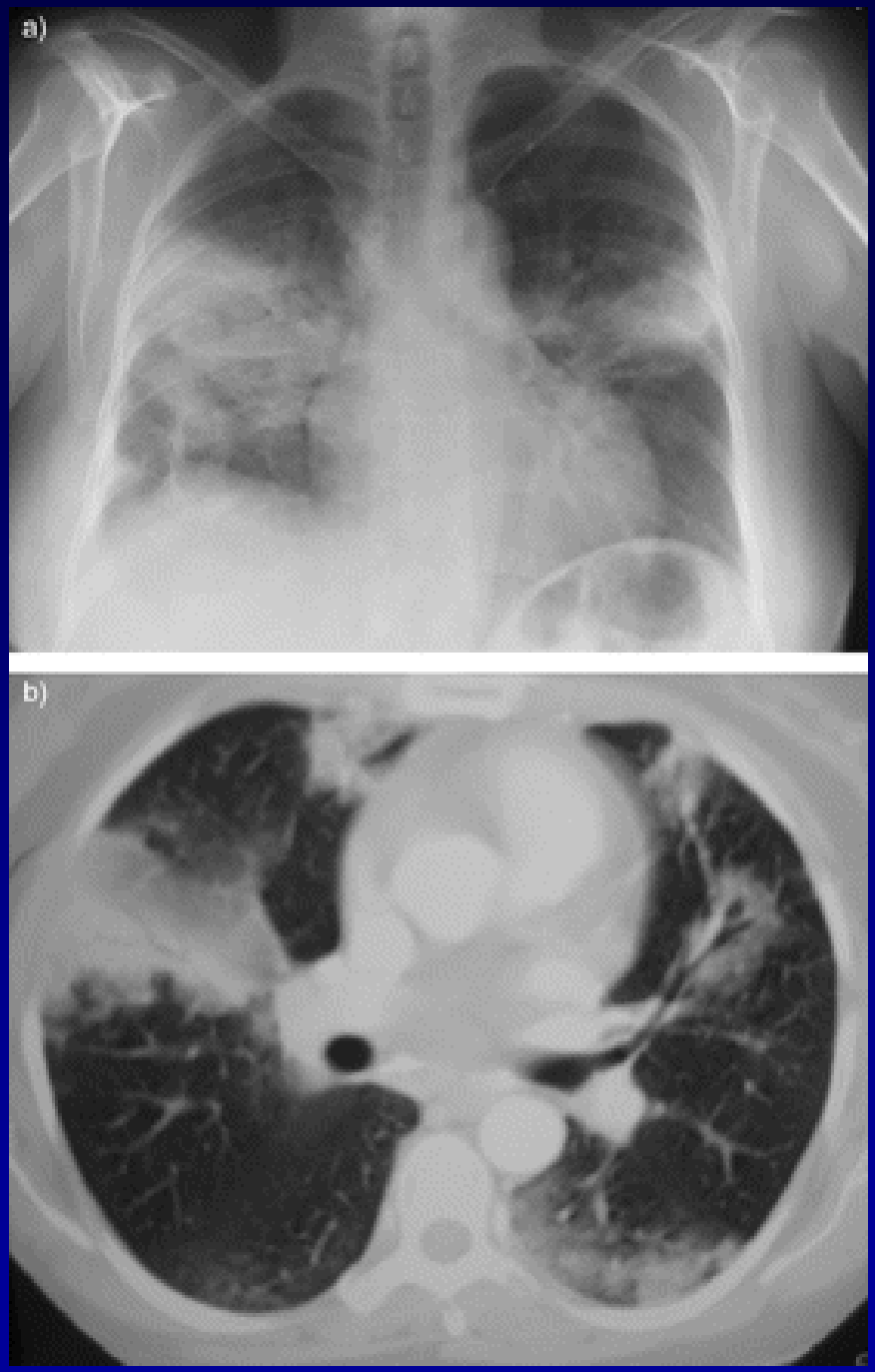
a)
b)

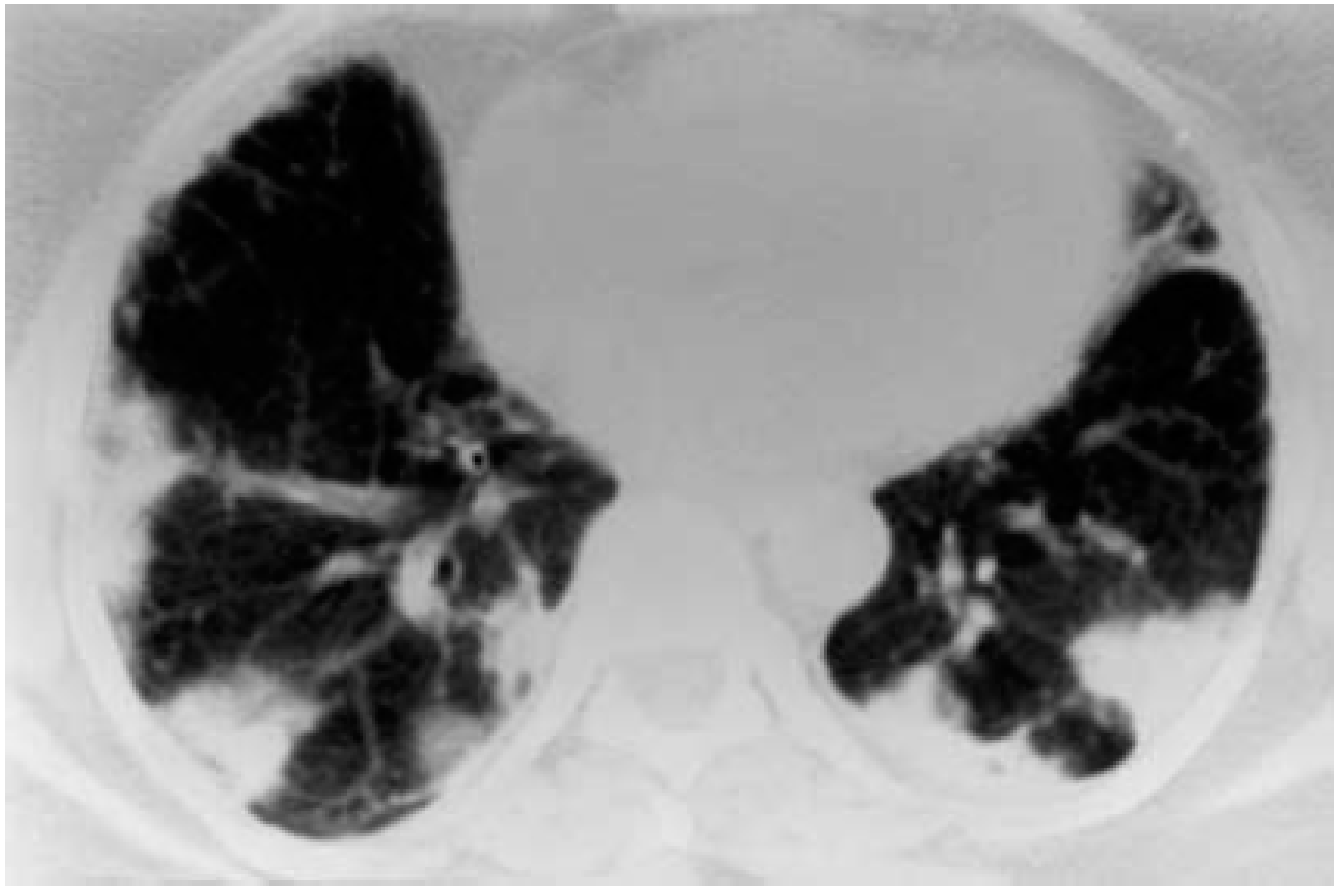

Fig. 2 A 58-year-old woman from Kuwait with a 6-month history of lethargy, night sweats and increasing breathlessness on exertion. A standard CT shows the typical CT features of cryptogenic organizing pneumonia. There are several basal and peripheral areas of air-space consolidation. A lung biopsy confirmed the diagnosis of organizing pneumonia

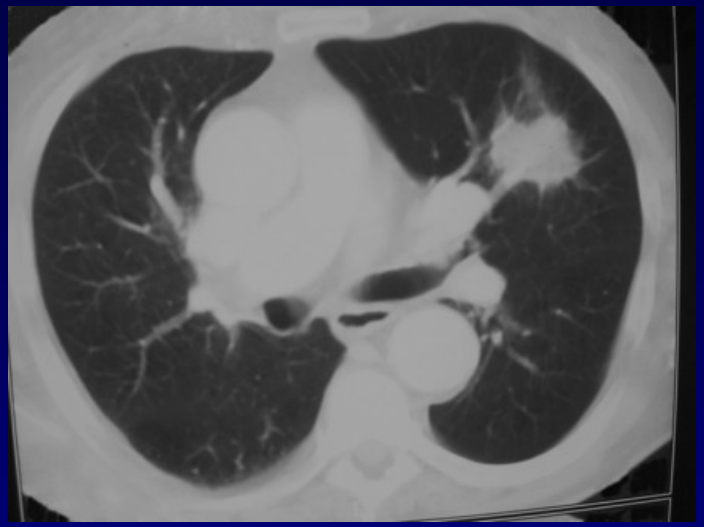

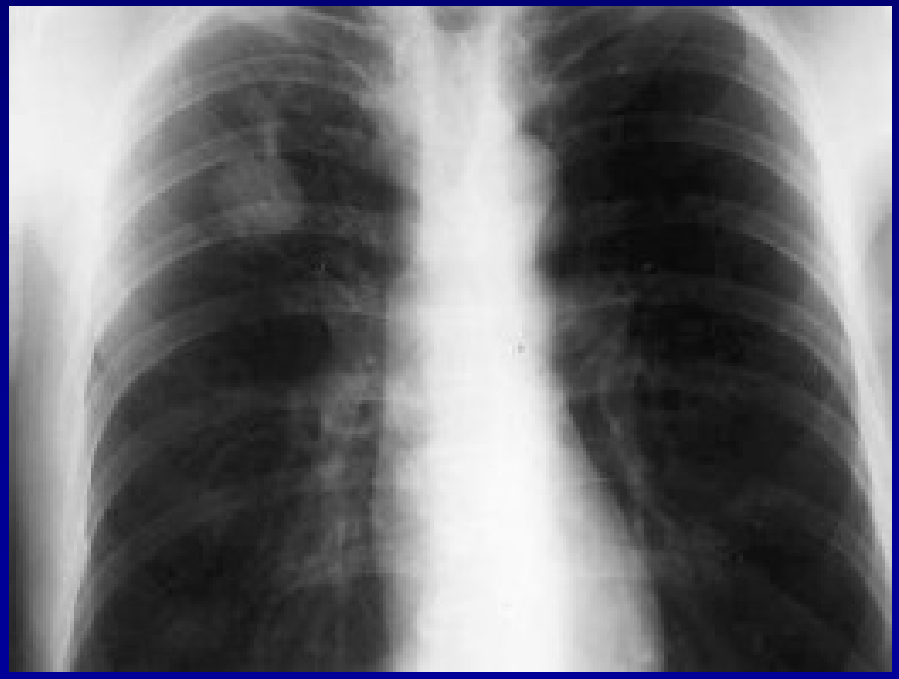

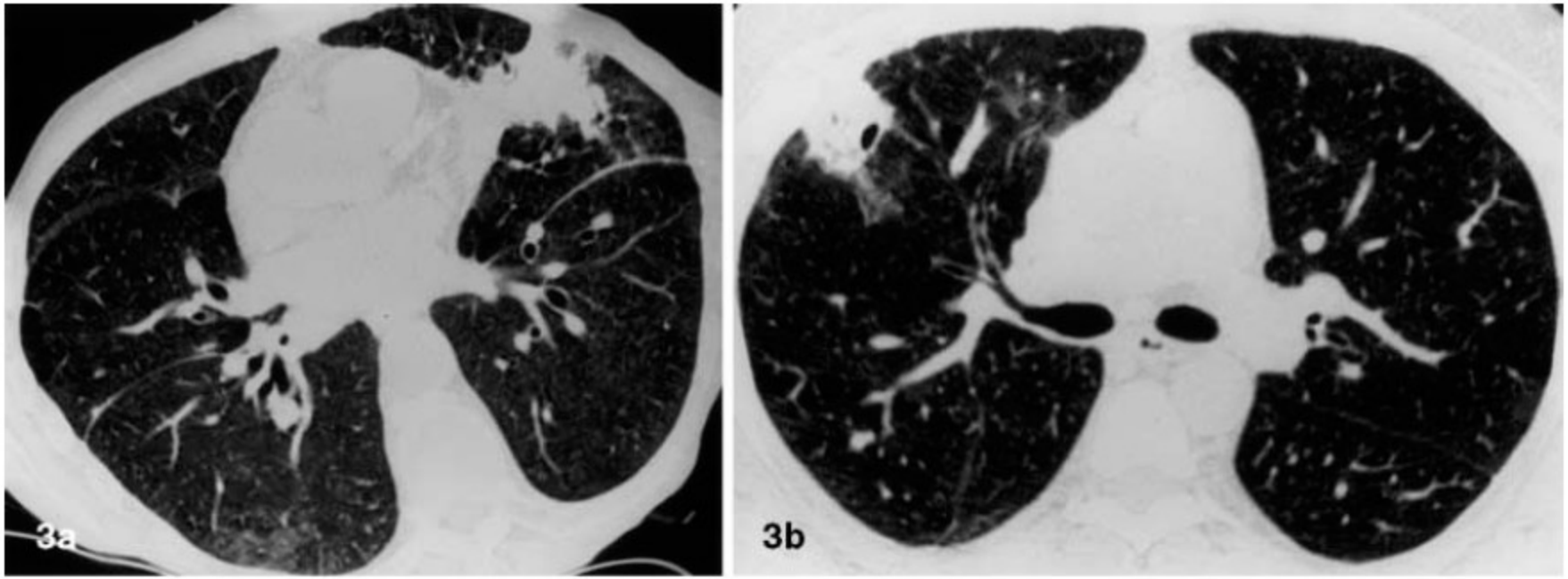

Fig. 3a, b Two examples of focal organizing pneumonia. **a** The mass-like lesion in the lingula was thought, at radiographic presentation, to represent a lung cancer. Note ground-glass opacity in the contralateral right lower lobe. **b** Patient with ulcerative colitis and focal cavitating lesion in the right upper lobe, shown to be a focus of organizing pneumonia on surgical resection

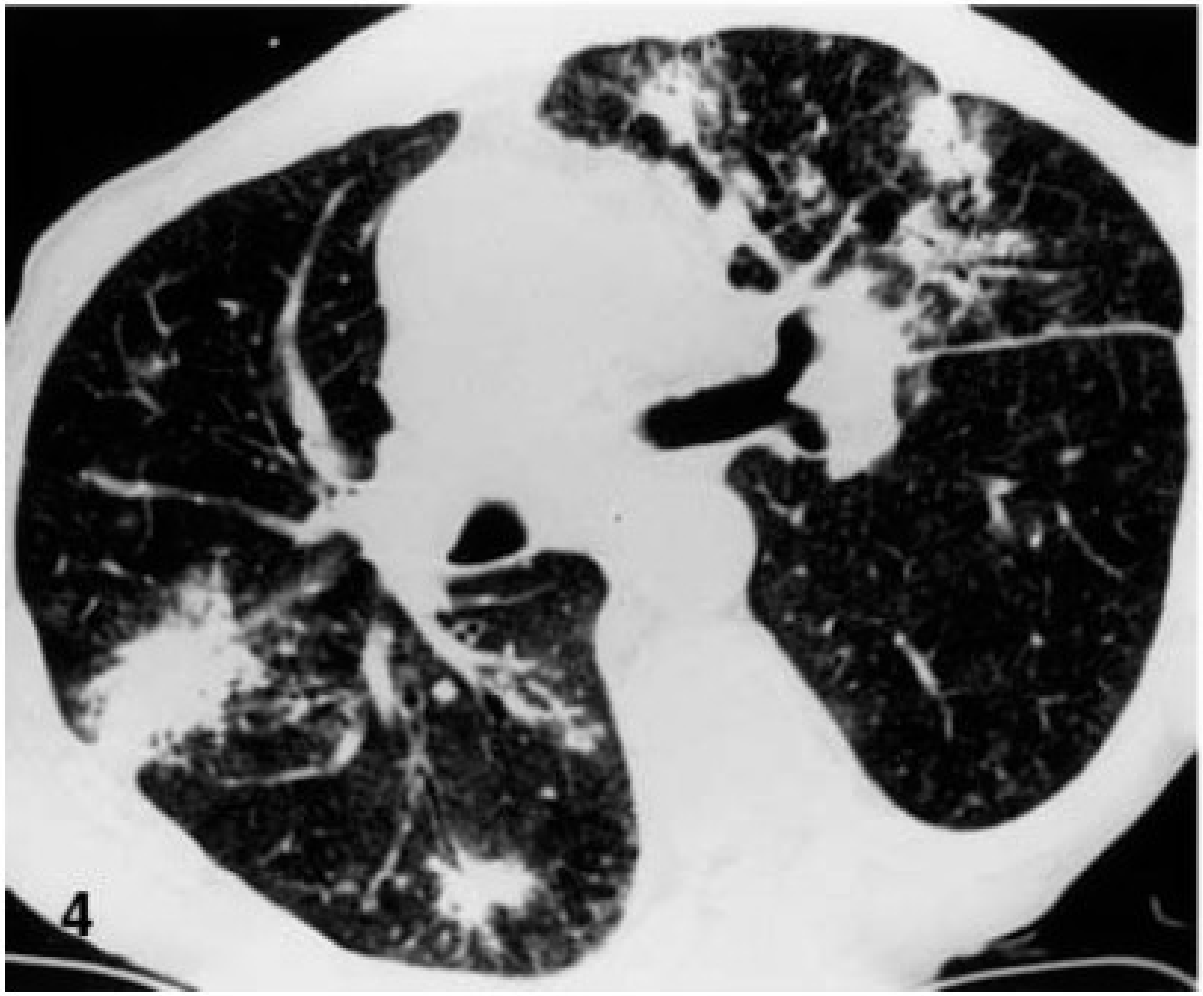

Fig. 4 A 59-year-old man with ulcerative colitis and insulin-dependent diabetes mellitus. The CT shows multiple focal mass-like lesions, some of which contain an air bronchogram. On biopsy these lesions proved to be areas of organizing pneumonia

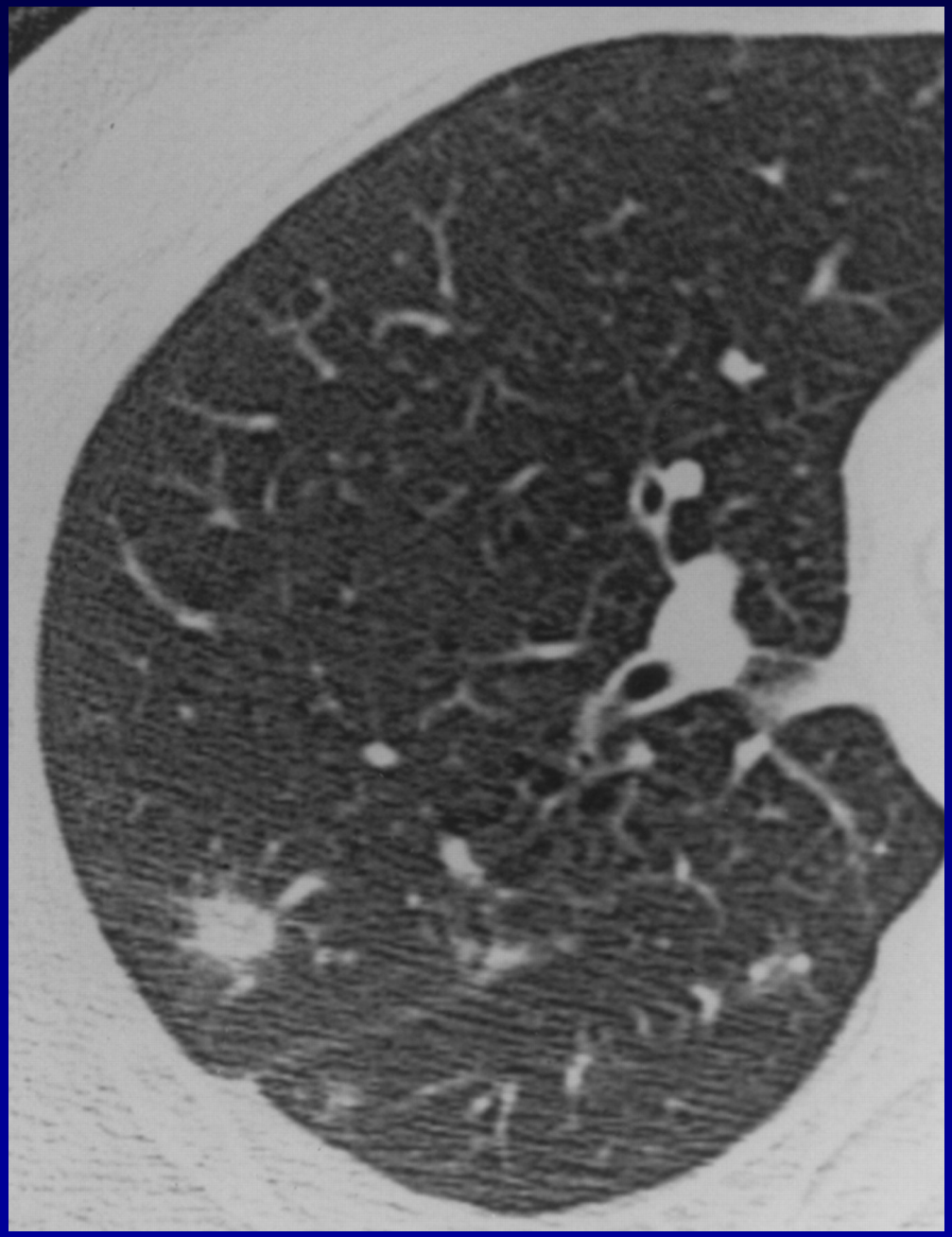

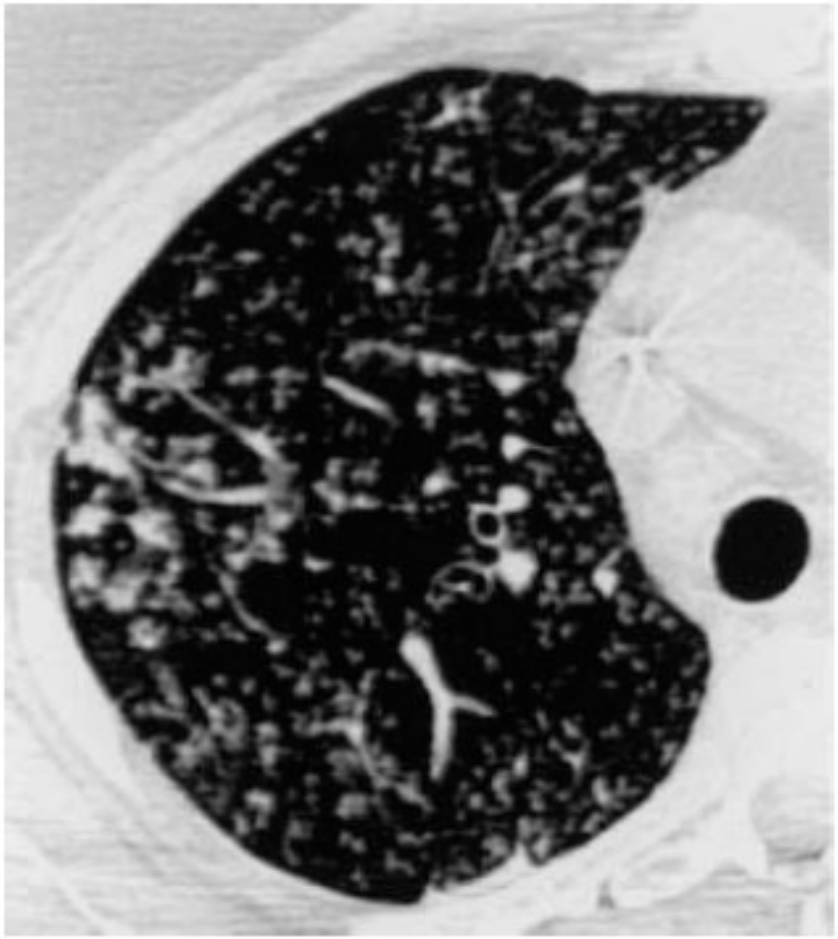

Fig. 5 A CT of the right upper lobe of a patient with a 10-day history of dyspnoea and suspected community acquired pneumonia. Combined pattern of peripheral "acinar" nodules and smaller nodules, some of which resemble a tree-in-bud pattern. Biopsy-proven organizing pneumonia. (Courtesy of S. Diederich, Muenster)

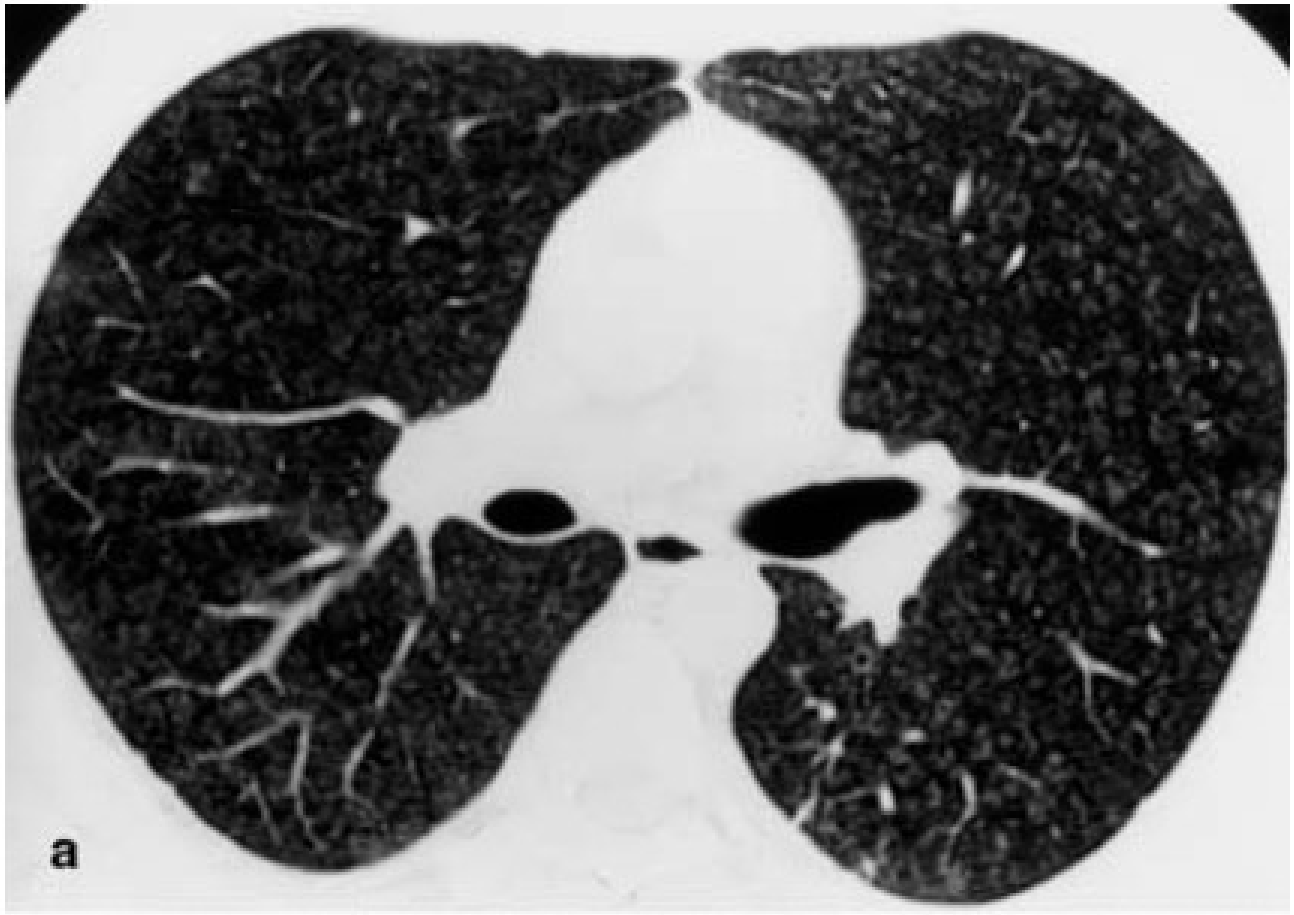

Fig. 6 **a** A 23-year-old bodybuilder gradually became severely dyspnoeic and ultimately required mechanical ventilation. The diagnosis of organizing pneumonia was confirmed on lung biopsy and he responded slowly to prolonged treatment with steroids (no specific cause was found). On CT there is a micronodular pattern characterized by small ill-defined centrilobular nodules of less than 5 mm. **b** Lung biopsy specimen showing discrete small foci of organizing pneumonia, surrounded by normal aerated lung

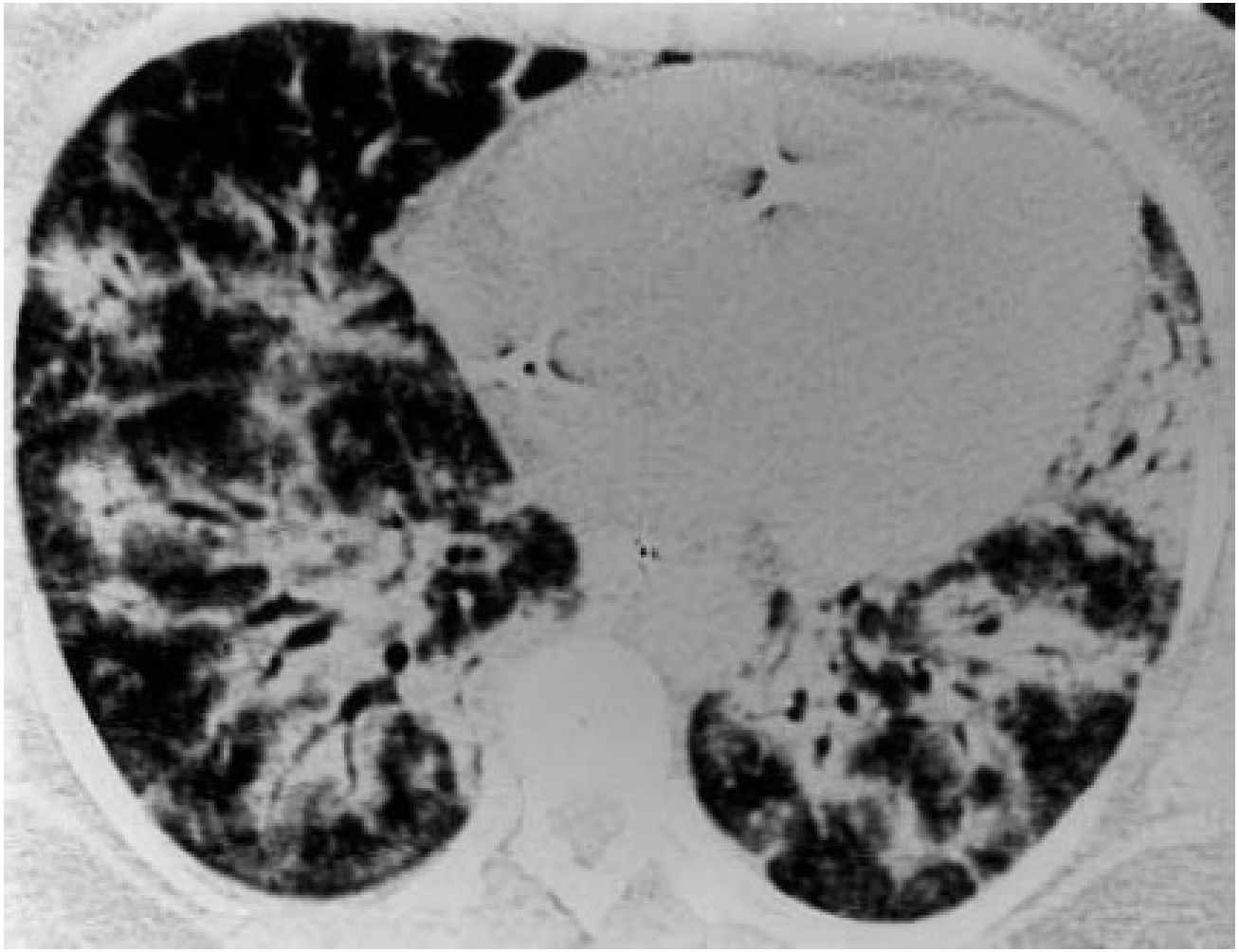

Fig. 7 Bronchocentric pattern of organizing pneumonia: areas of consolidation surround the bronchovascular bundles in a patient admitted to intensive care

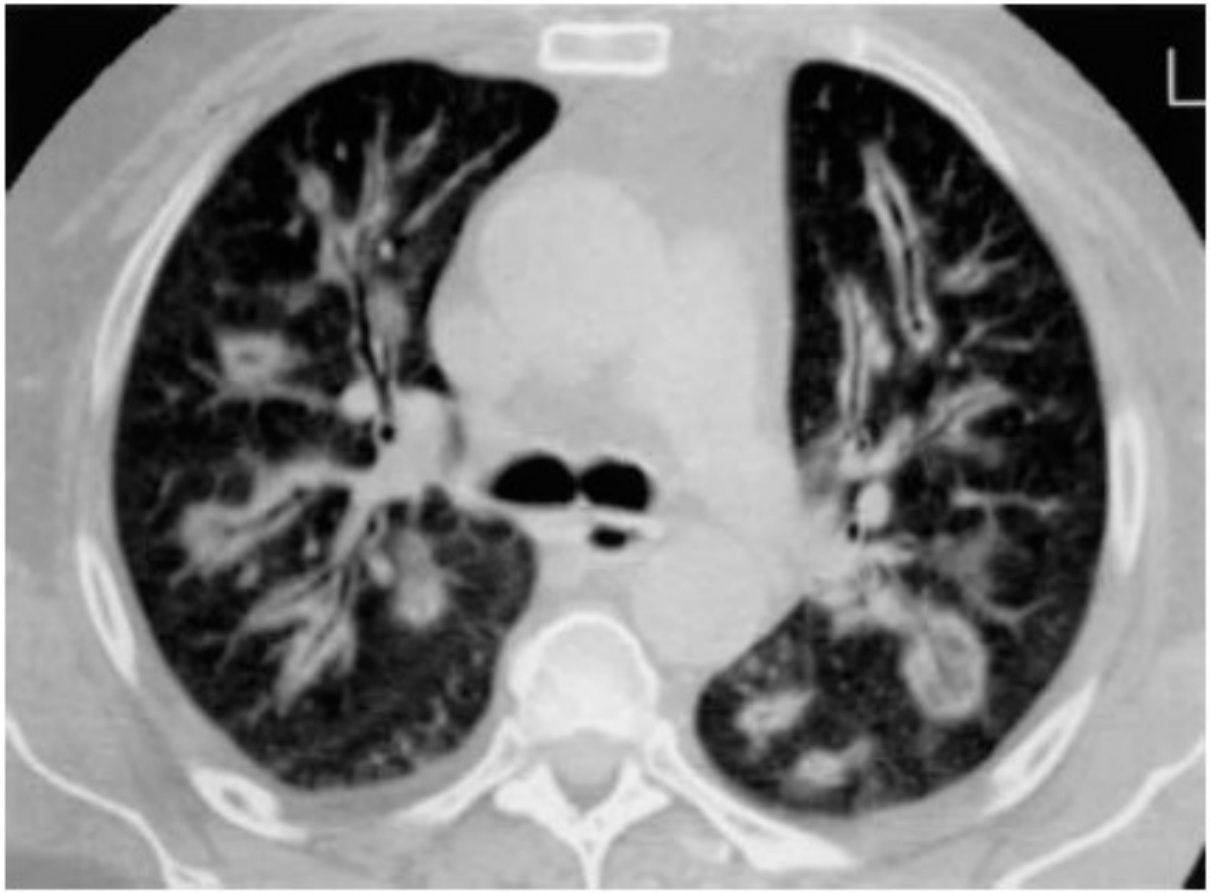

Fig. 8 Bronchocentric pattern of organizing pneumonia: a strikingly peribronchovascular distribution in a diabetic patient with biopsy proven organizing pneumonia. (Courtesy of A. Vathi, Bolatti, Milan)

Fig. 9 A 41-year-old man developed cryptogenic organizing pneumonia concurrent with an episode of pericarditis. On CT there are bilateral band-like opacities, both of which contain an air-bronchogram. Biopsy of one of these lesions confirmed organizing pneumonia

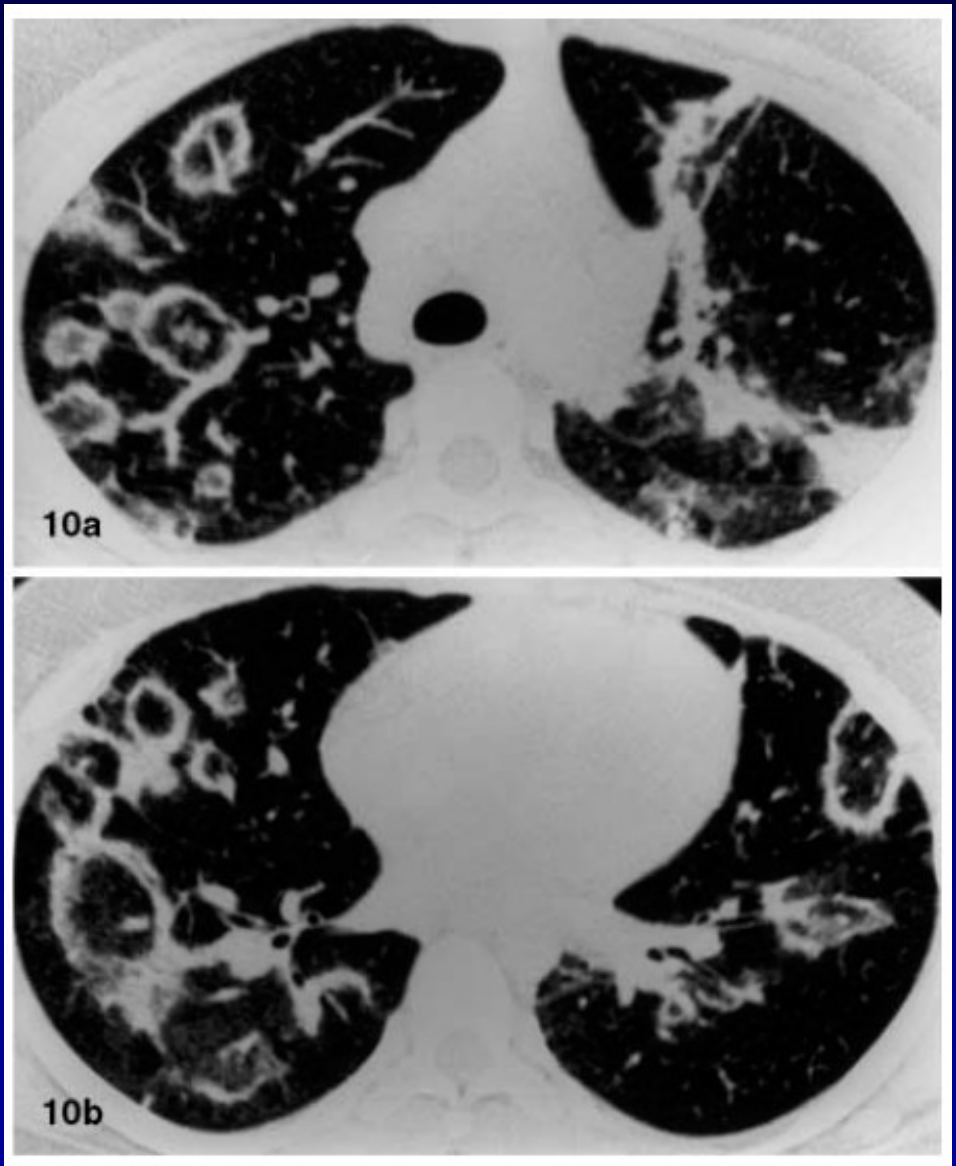

Fig. 10a, b A CT scan of a 14-year-old boy not responding to treatment for suspected tuberculosis (later excluded). A striking pattern of ring-like opacities surrounding areas of ground-glass opacification is seen in the **a** upper and **b** lower lobes. Open-lung biopsy revealed organizing pneumonia

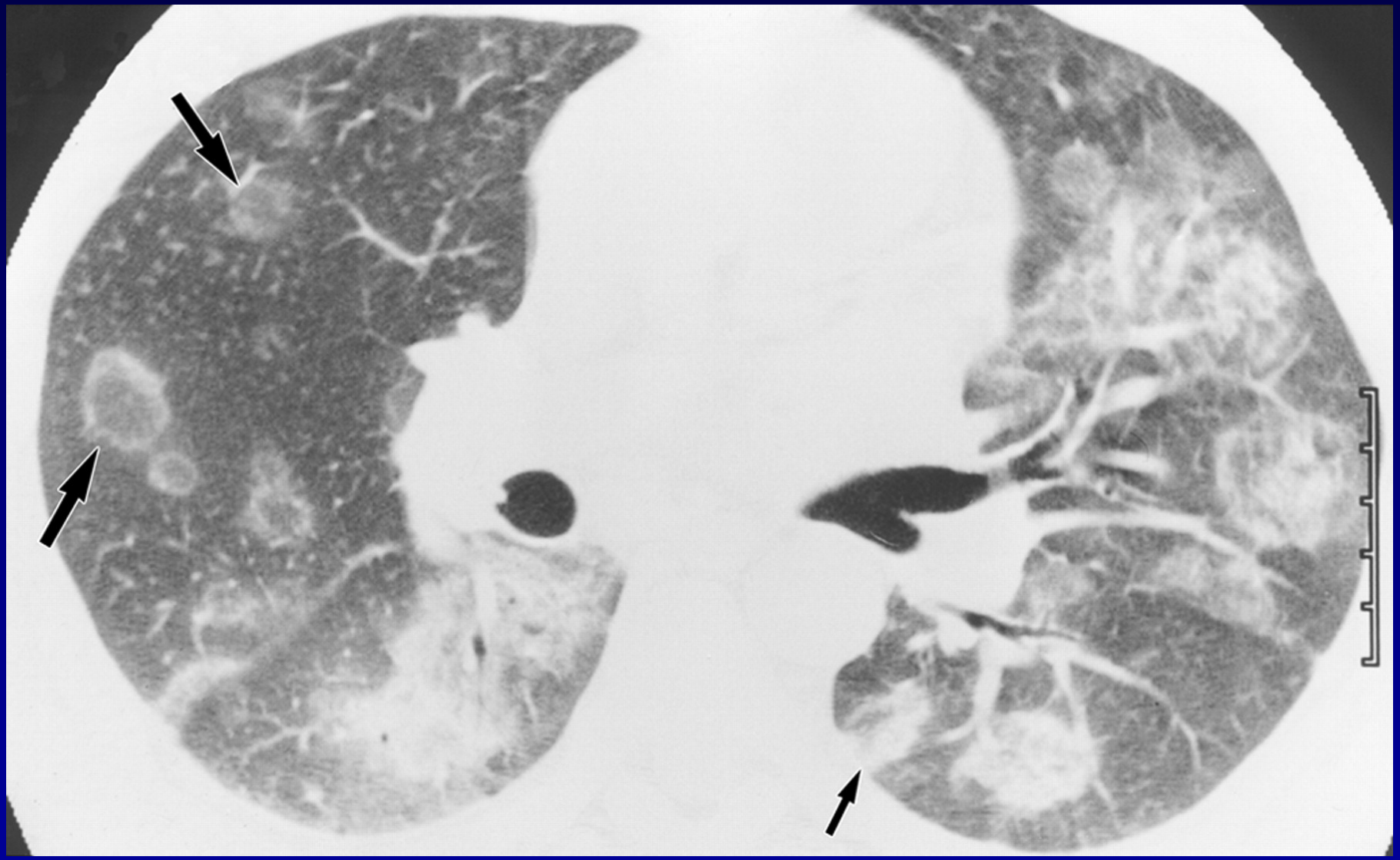

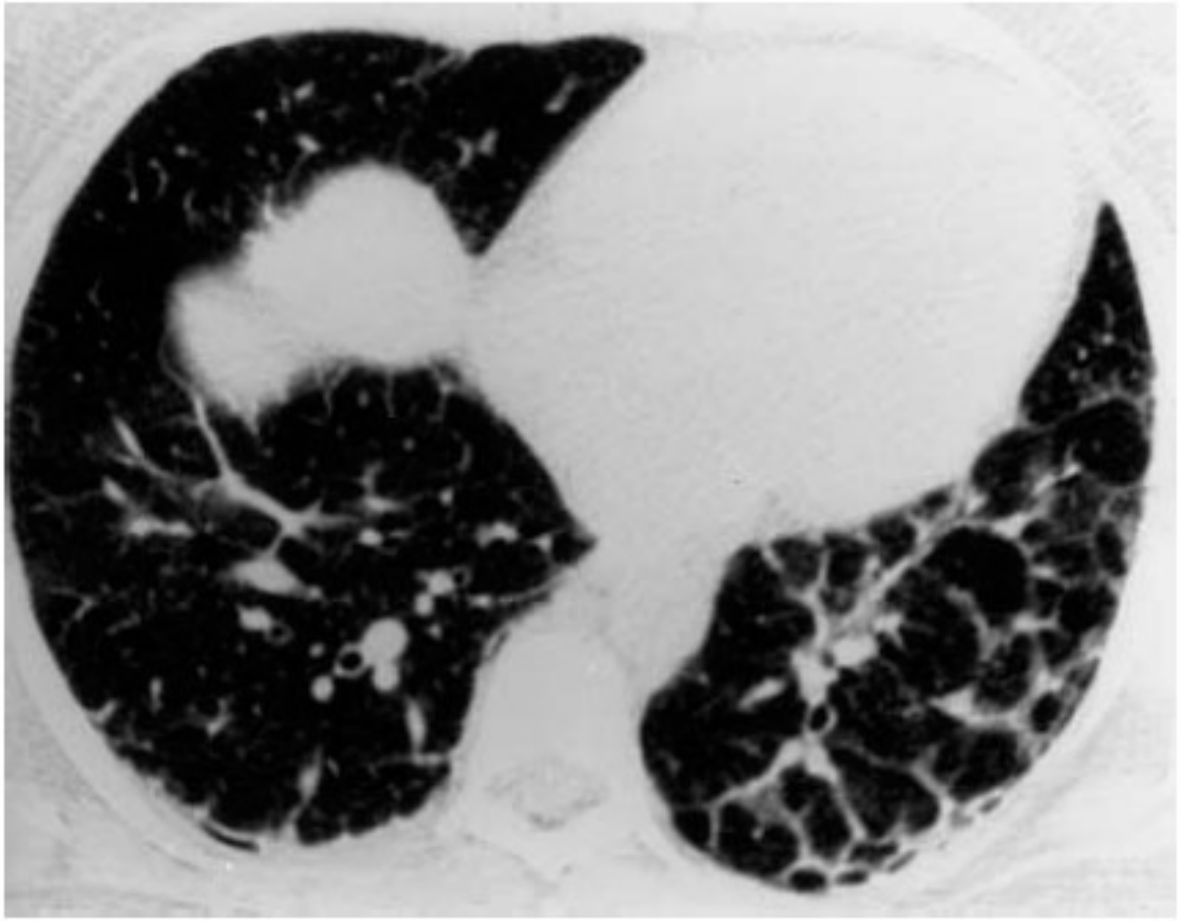

Fig. 12 A perilobular pattern of organizing pneumonia. There is opacification around the periphery of individual secondary lobules resembling poorly defined thickened interlobular septa

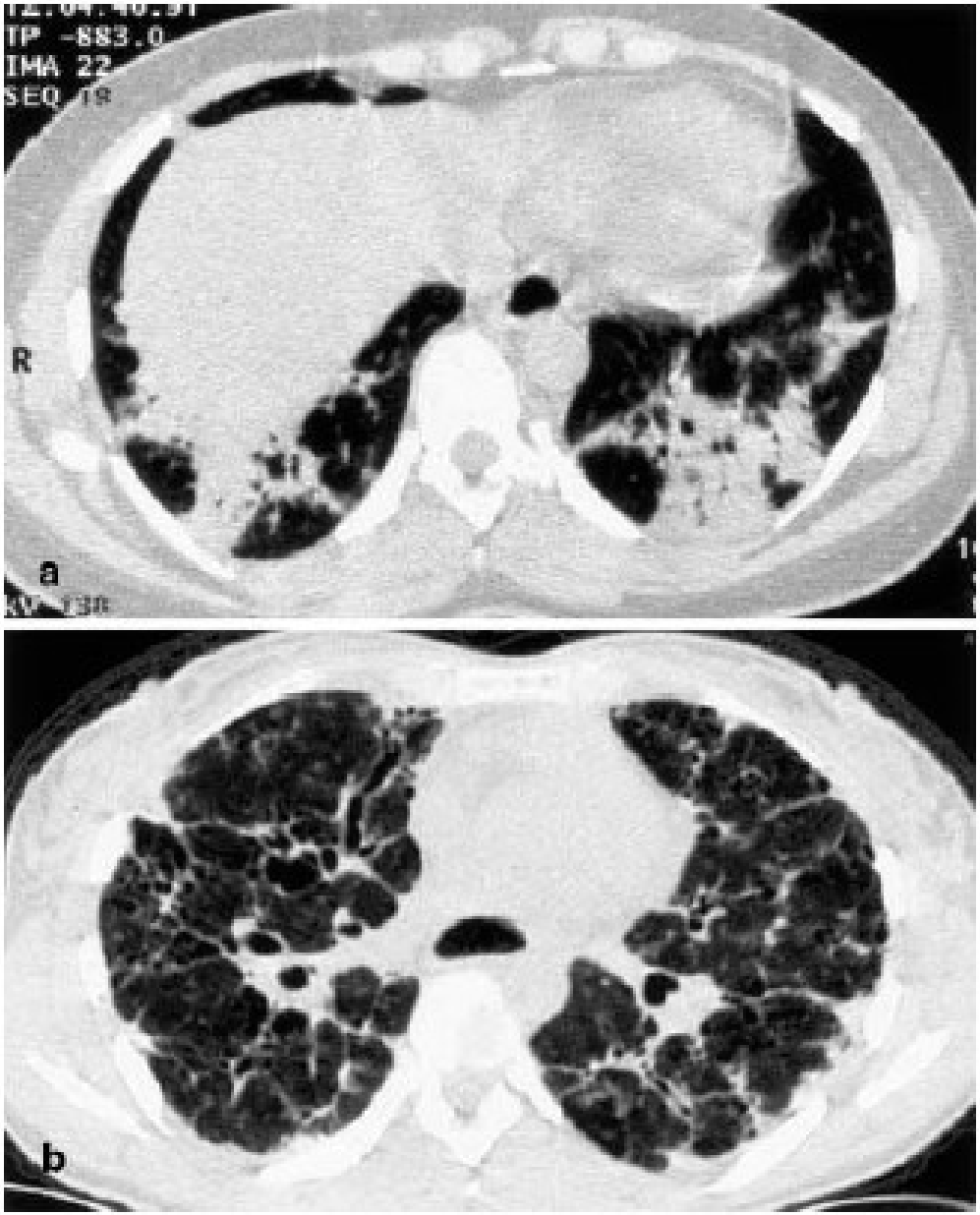

Fig. 13a, b A 36-year-old woman presented with the presumptive diagnosis of bronchopneumonia, with minor improvement on antibiotics; however, exertional dyspnoea and a restrictive ventilatory defect remained. **a** The initial CT showed patchy areas of consolidation concentrated in the lower lobes, but no obvious features established interstitial fibrosis. **b** The same patient 15 months later after prolonged steroid treatment. The areas of consolidation had largely resolved, but an extensive coarse reticular pattern, indicating supervening fibrosis, had developed

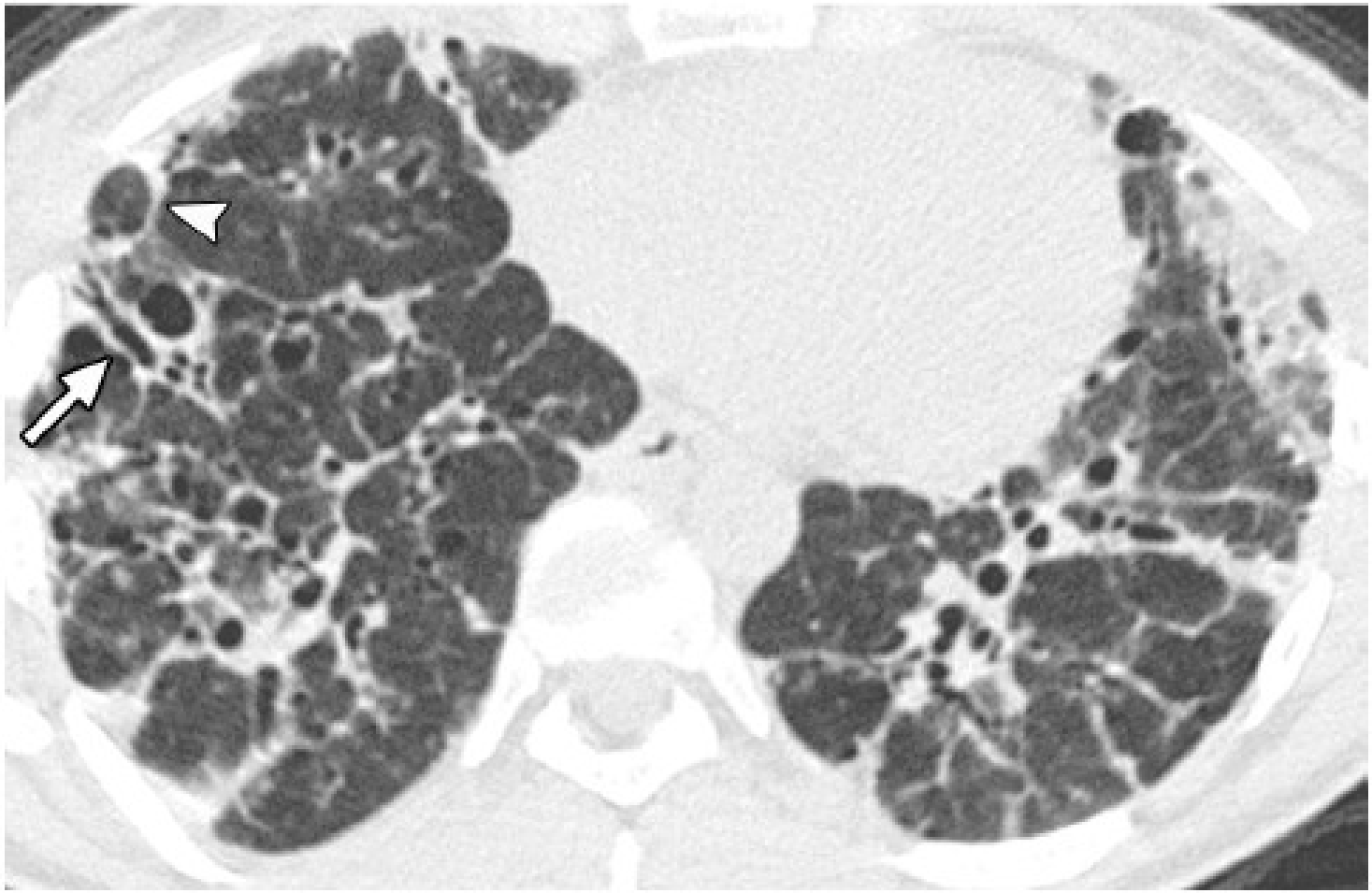

Figure 6. Transverse thin-section CT scan through lower lobes in a 37-year-old woman with cryptogenic organizing pneumonia. There is perilobular opacity (arrowhead) and dilatation and distortion of airways (arrow) indicating presence of interstitial fibrosis.

Idiopathic bronchiolitis obliterans with organizing pneumonia. An acute and life-threatening syndrome

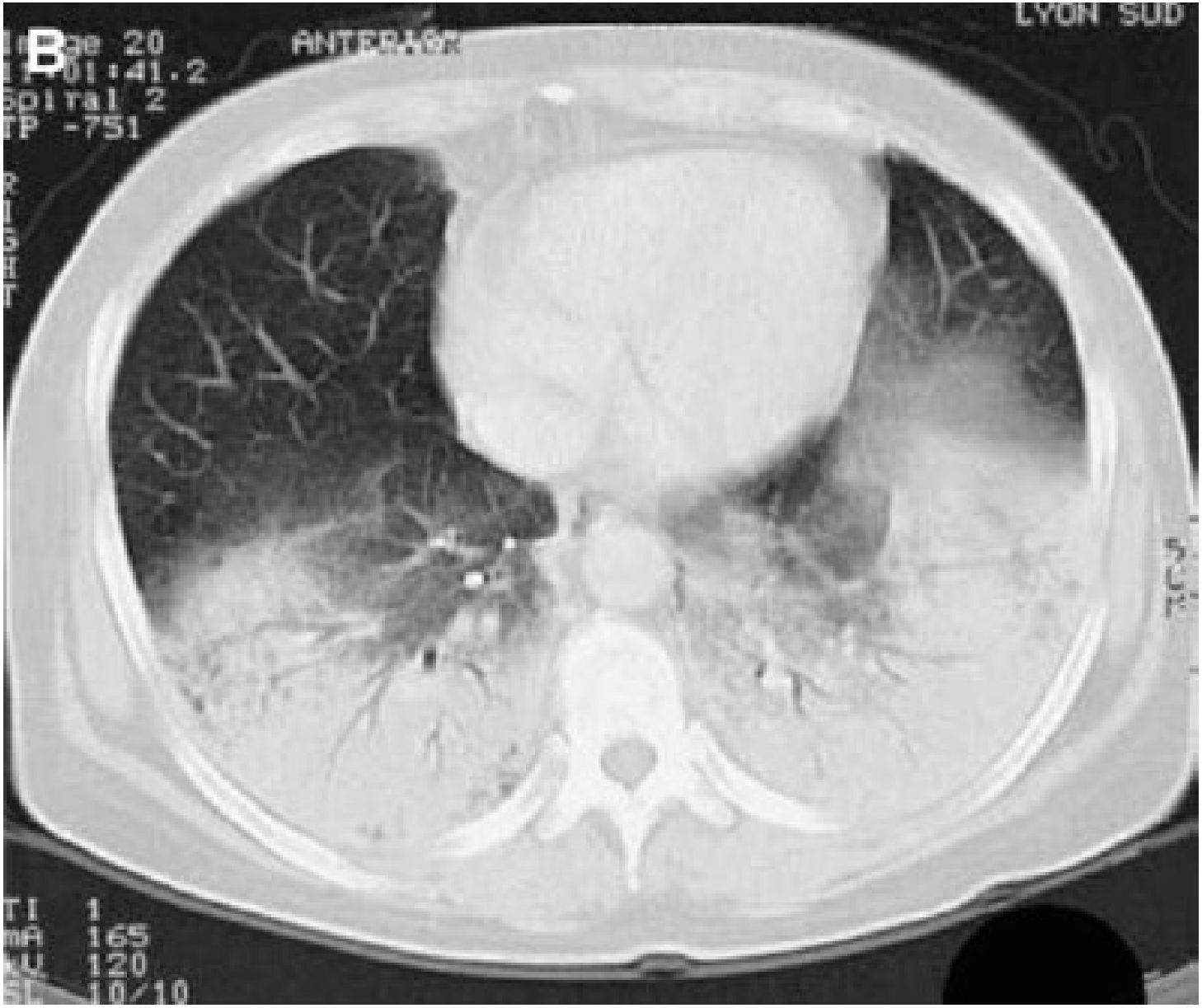

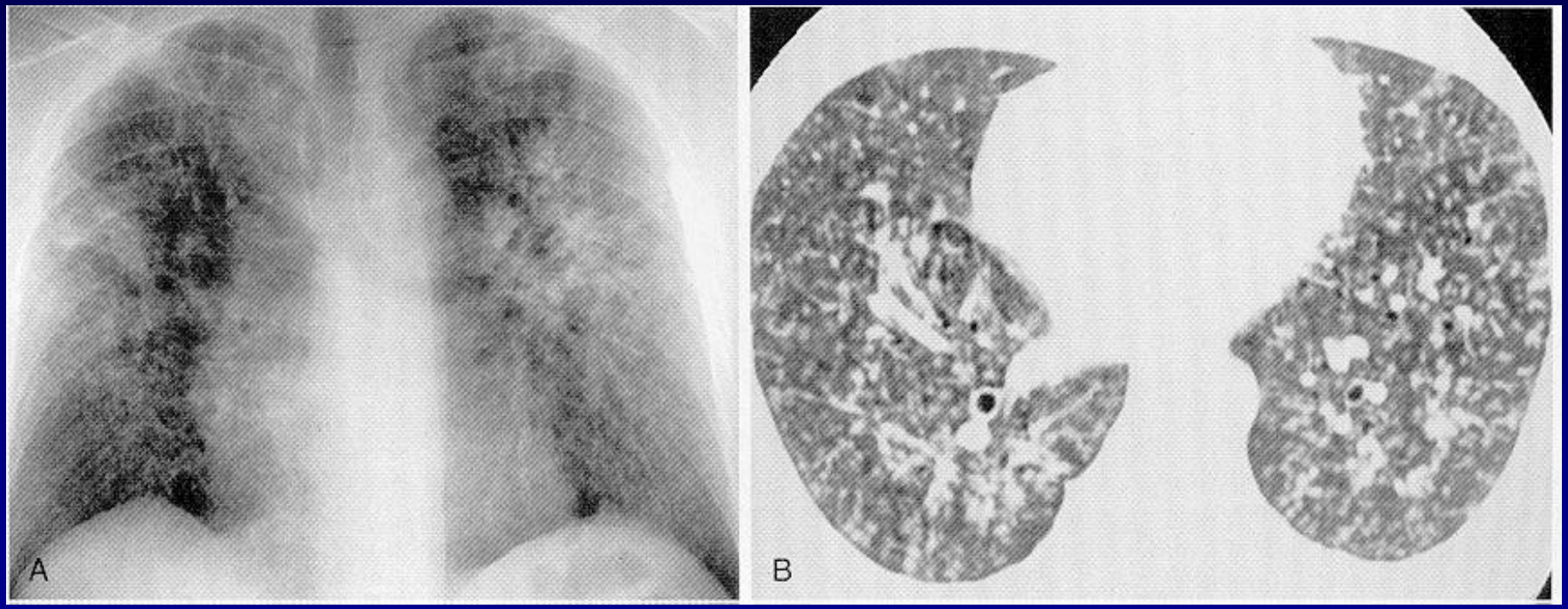
A
B

TABLE 5–5 Cell Differentials in Bronchoalveolar Lavage

	*Total Cells**	*Macrophages (%)*	*Lymphocytes (%)*	*Neutrophils (%)*	*Eosinophils (%)*	*Mast cells (%)*	*Plasma cells (%)*	*Foamy macrophages (%)*
Control nonsmokers	7 ± 3	92 ± 4	7 ± 3	1 ± 1	0.1 ± 0.3	0.1 ± 0.1	–	–
Control smokers	23 ± 12	96 ± 3	3 ± 2	1 ± 1	0.4 ± 0.6	0.1 ± 0.3	–	–
Sarcoidosis	16 ± 17	55 ± 21	41 ± 21	3 ± 5	1 ± 1	0.4 ± 0.5	–	–
Extrinsic allergic alveolitis	34 ± 22	18 ± 10	78 ± 10	2 ± 2	1 ± 1	0.9 ± 0.9	0.8 ± 0.9	22 ± 17
Idiopathic pulmonary fibrosis (IPF)	14 ± 11	66 ± 23	15 ± 15	14 ± 16	5 ± 5	0.3 ± 0.7	–	14 ± 13
Bronchiolitis obliterans organizing pneumonia (BOOP)	14 ± 9	39 ± 19	44 ± 19	10 ± 13	6 ± 8	1.0 ± 0.4	0.1 ± 0.1	25 ± 10
Chronic eosinophilic pneumonia	18 ± 22	27 ± 18	22 ± 18	6 ± 6	46 ± 22	1.0 ± 0.9	0.7 ± 0.4	6 ± 11

Adapted from Costabel U.[39]

BALF

- Less in volume but greater number of cells
- % mac is lower in COP
- % lympho, neu and eos> healthy
- >CD8, increased Th1 cytokines
- Foamy mac
- Increase in activated T- cells (CD25 expression)

Role of Transbronchial biopsies

- 64% sensitivity and 86% specificity

- ***VATS could be omitted:***
- a) typical COP pattern on CT;

- b) compatible clinical presentation;

- c) compatible transbronchial biopsy;

- d) bronchoalveolar lavage showing foamy macrophages, lymphocytes more than 25% with a CD4/CD8 ratio of less than 0.9 combined with at least 2 of the following criteria:
- foamy macrophages, 20% and/or neutrophils of 5% *and/or* eosinophils >2% and less than 25%;

- e) absence of an underlying disorder (which can cause OP).

Poletti V, ERJ 1996

Differential diagnosis

- Bacterial pneumonia
- Diffuse alveolar damage (ARDS)
- HP
- CEP
- Pulmonary drug reaction
- Pulmonary disease associated with CTD

Organising pneumonia

Jean-François Cordier

The diagnosis of COP without a biopsy is seldom justified. It may be considered in patients who are critically ill (particularly older

VAT is a safe procedure that may be used in most patients

relatively high doses of corticosteroids (over 25 mg per day) should lead the clinician to suspect other diagnoses, particularly lymphomas.[131]

TABLE 10. HISTOLOGIC FEATURES OF ORGANIZING PNEUMONIA PATTERN

Key Histologic Features
Organizing pneumonia: intralumenal organizing fibrosis in distal airspaces (bronchioles, alveolar ducts, and alveoli)
Patchy distribution
Preservation of lung architecture
Uniform temporal appearance
Mild interstitial chronic inflammation
Pertinent Negative Findings
Lack of interstitial fibrosis (except for incidental scars or apical fibrosis)
Absence of granulomas
Lack of neutrophils or abscesses
Absence of necrosis
Lack of hyaline membranes or prominent airspace fibrin
Lack of prominent infiltration of eosinophils
Absence of vasculitis

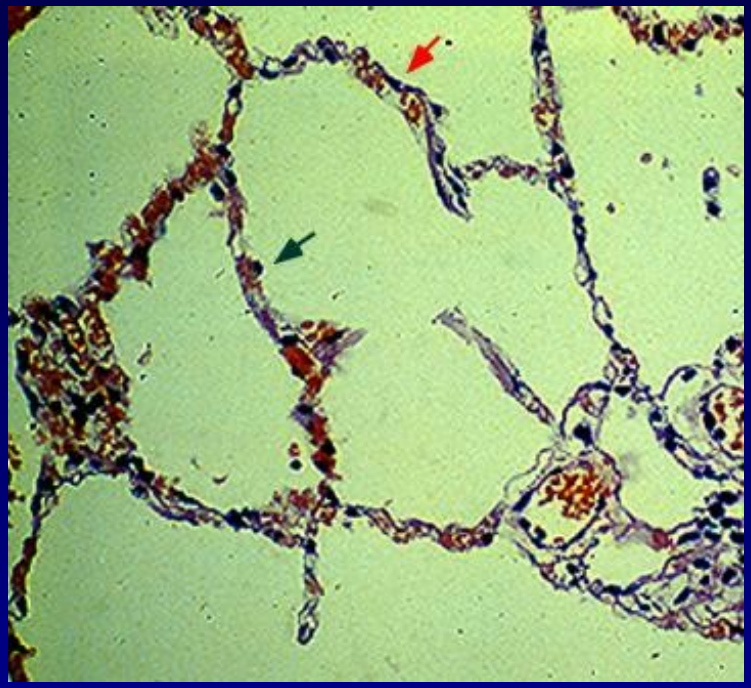

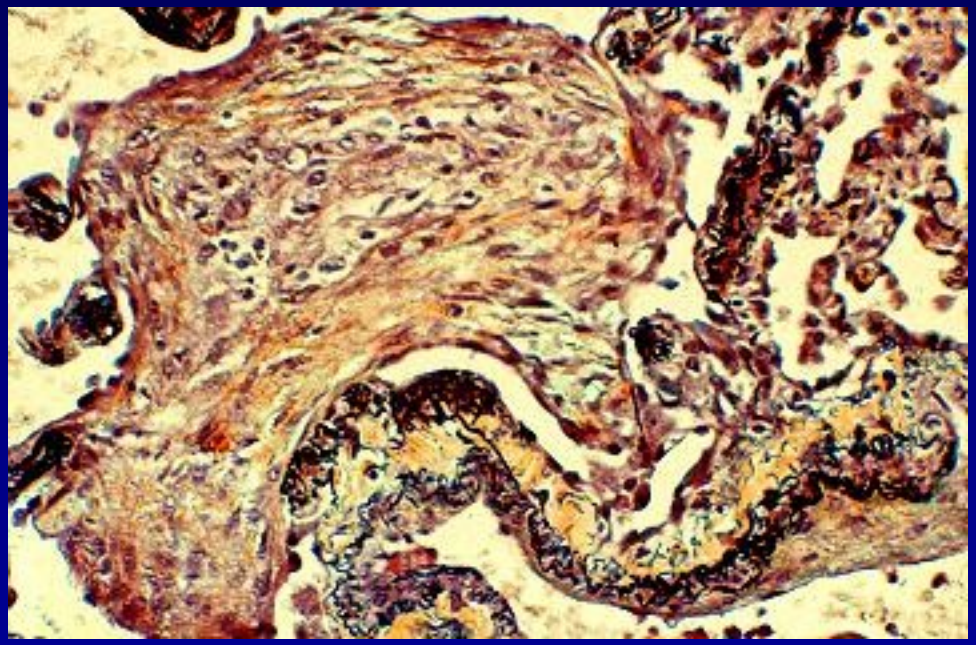

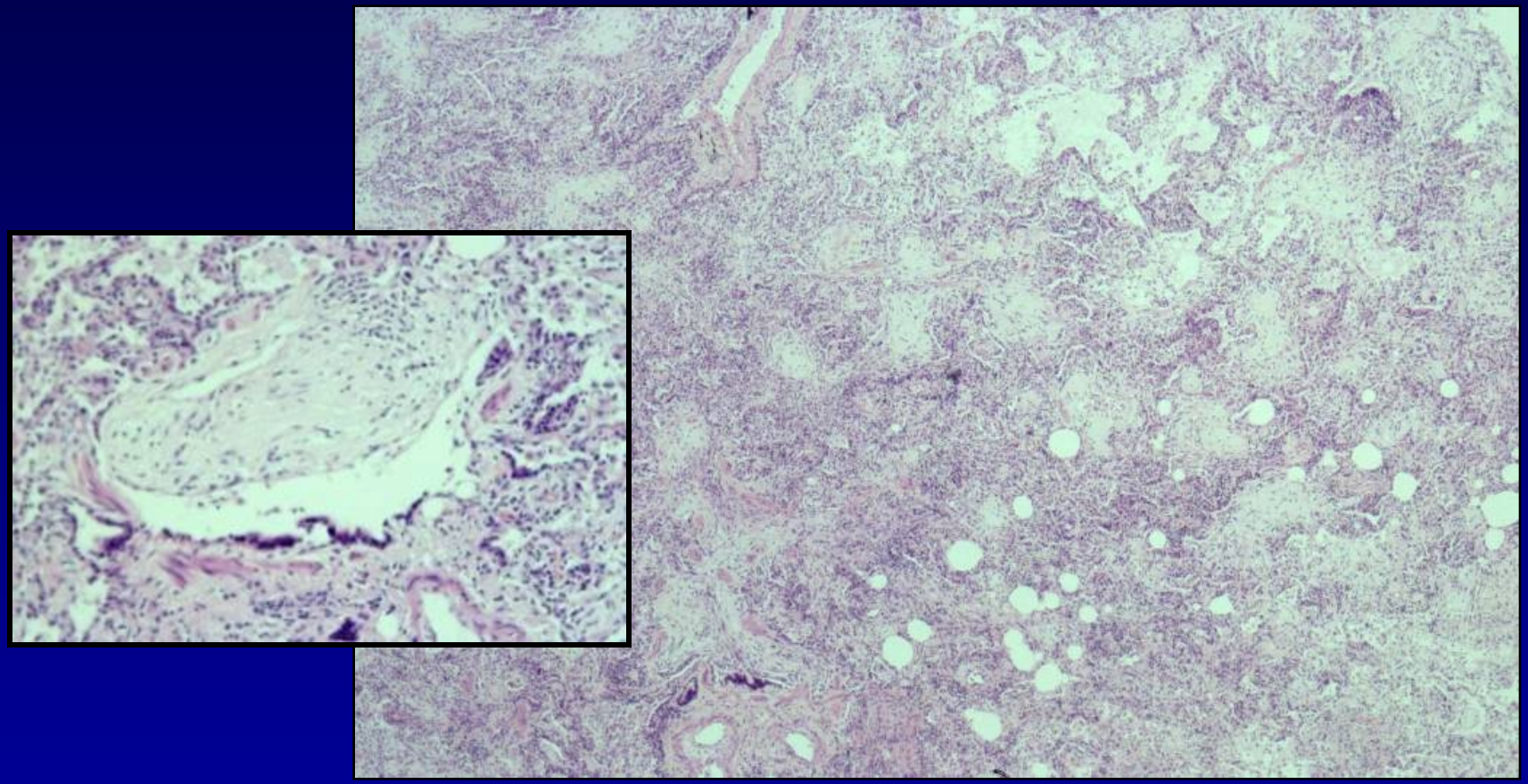

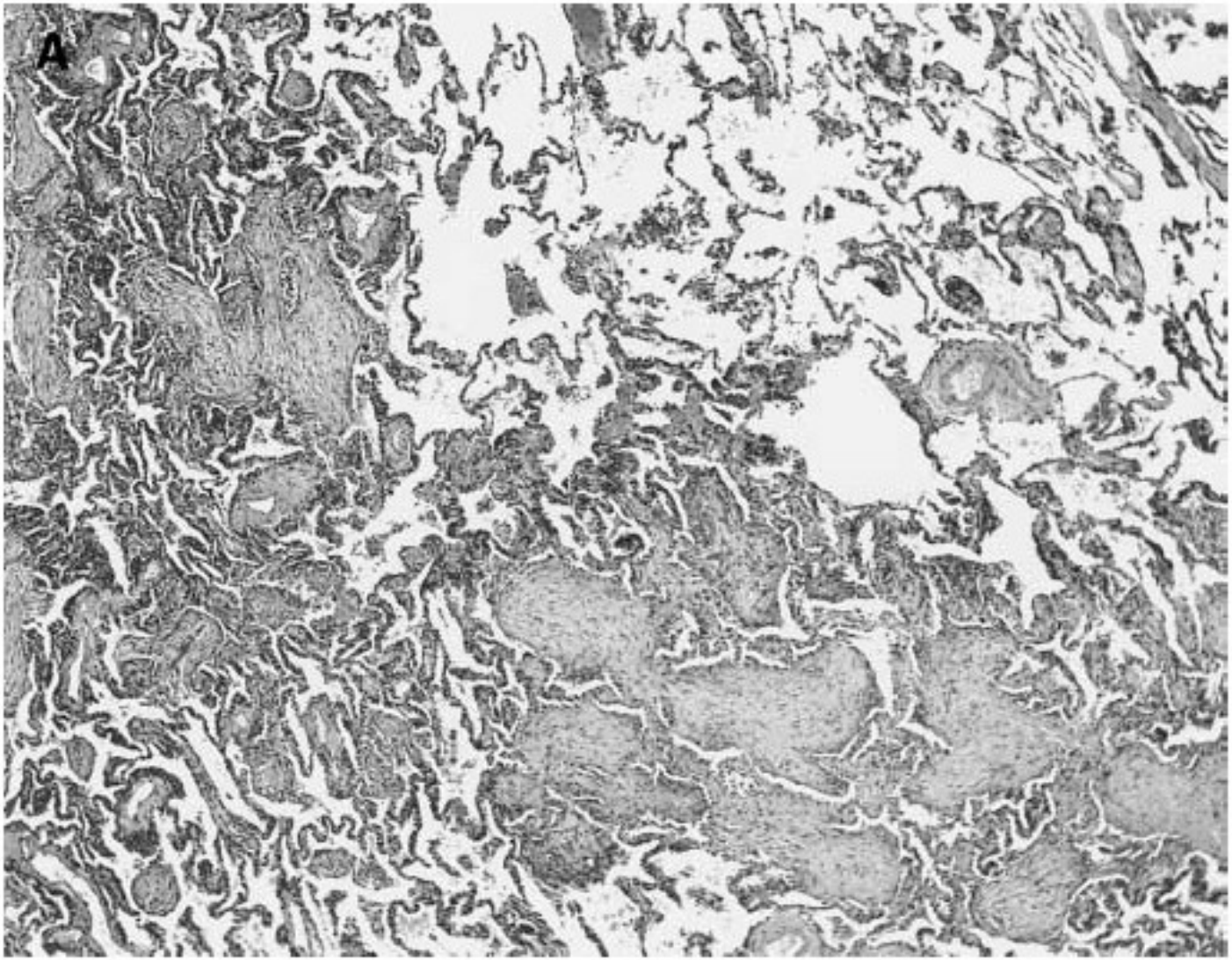
A

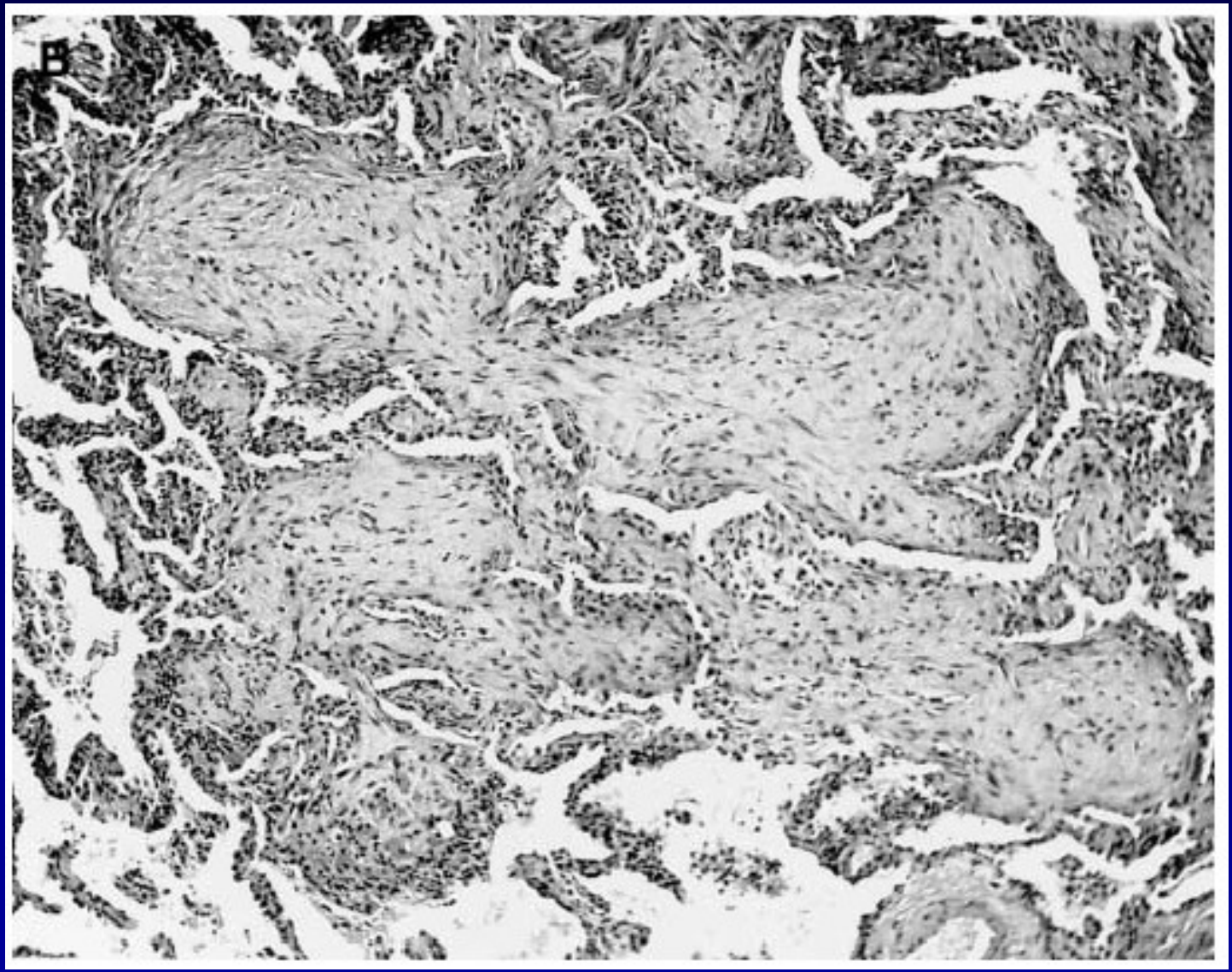
B

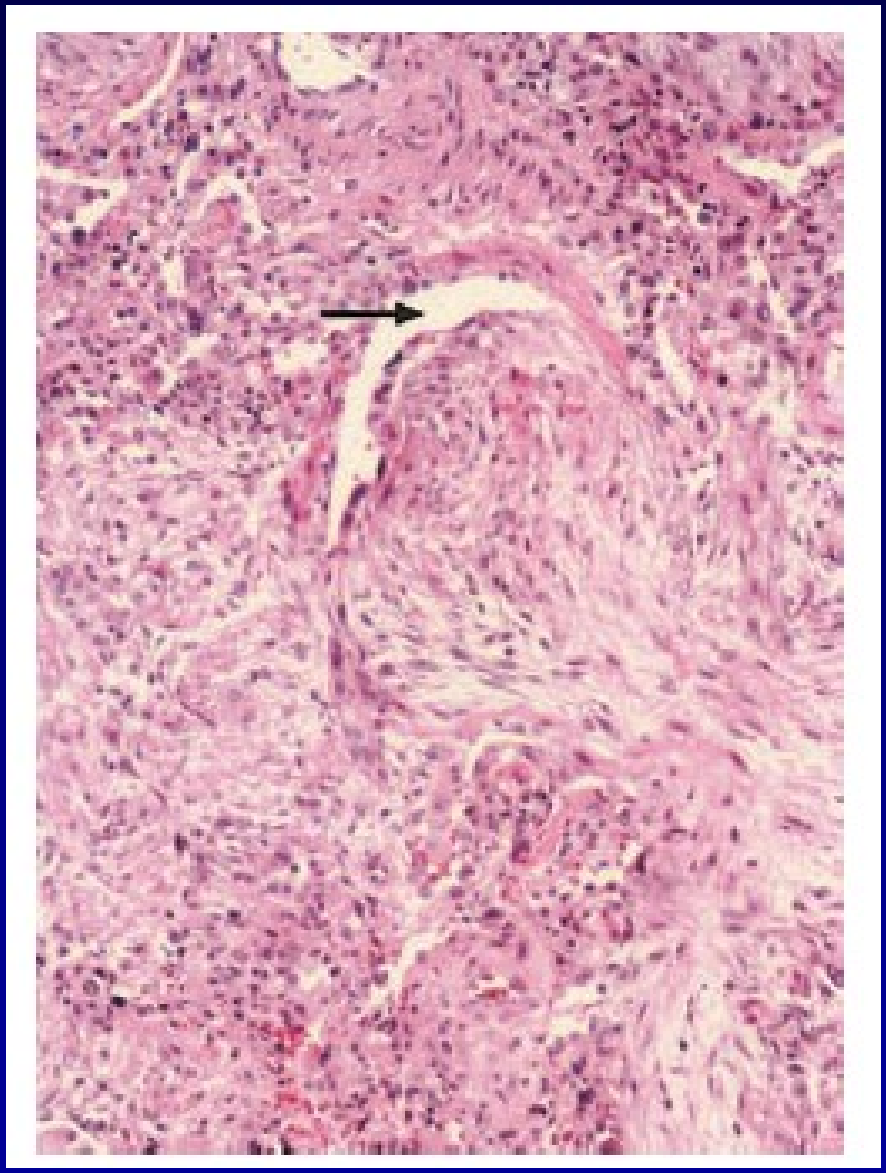

TABLE 1 Typical distinctive characteristics of cryptogenic organising pneumonia (COP), idiopathic nonspecific interstitial pneumonia (NSIP) and idiopathic pulmonary fibrosis (IPF)

	COP	Idiopathic NSIP	IPF
Histopathological pattern	Organising pneumonia	NSIP	Usual interstitial pneumonia
Histopathological features	Preserved lung architecture, intralumenal buds of granulation tissue in the distal airspaces (alveoli and alveolar ducts, possibly bronchioles); mild interstitial chronic inflammation; patchy distribution	Temporal and spatial homogeneity, mild-to-moderate interstitial inflammation (usually lymphocytic) with intra-alveolar organising fibrosis (minor component) and lack of interstitial fibrosis (cellular NSIP pattern); dense or loose interstitial fibrosis with mild or moderate interstitial chronic inflammation (fibrosing NSIP pattern)	Architectural destruction; temporal and spatial heterogeneity (areas of normal lung present); interstitial fibrosis with honeycombing; fibroblastic foci
Mean age yrs	50–60	40–50	60–70
Onset	Subacute	Chronic/subacute	Chronic
Clinical manifestations	Mild dyspnoea, cough, fever, sparse crackles; no finger clubbing	Moderate-to-severe dyspnoea, cough; diffuse crackles; finger clubbing uncommon	Severe dyspnoea, cough; severe restrictive ventilatory defect at lung function tests, with marked hypoxaemia; diffuse crackles; finger clubbing common
Imaging features#	Patchy areas of consolidation (peripheral, bilateral, possibly migratory, air bronchogram)	Ground-glass opacities and reticulation, basal predominance	Reticular abnormalities, honeycombing, traction bronchiectasis (peripheral, basal)
BAL	Mixed pattern (mild increase in lymphocytes, neutrophils, eosinophils)	Increase in lymphocytes (and possibly neutrophils)	Increase in neutrophils (and possibly eosinophils)
Prognosis	Excellent without sequelae	Very good (cellular pattern); rather poor (fibrosing pattern)	Poor
Response to corticosteroid treatment	Excellent	Usually good (cellular pattern); usually moderate or poor (fibrosing pattern)	Poor

Acute Cryptogenic organizing pneumonia

- Acute fulminant COP without pulmonary fibrosis presents as the Adult Respiratory Distress Syndrome (ARDS)
- Typical OP at biopsy or autopsy
- A rare presentation which is occasionally rapidly fatal and often requires mechanical ventilation
- In survivors a rapid response to corticosteroid therapy is usual

BOOP (COP)

treatment

- **Corticosteroid therapy is the most common treatment.**
- **Complete clinical recovery, physiological improvement, and normalization of the chest film are seen in two thirds of patients**
- **Approximately one-third demonstrate persistent disease.**
- **Delay in treatment increases the risk of more severe disease and relapses**

Cordier J-F, Eur Respir J 2006

BOOP (COP)

treatment

The dose of oral corticosteroids needed to treat patients with COP is not known. The author's experience is with high-dose oral corticosteroid therapy as described for other idiopathic interstitial pneumonias. High-dose parenteral corticosteroid therapy (eg, methylprednisolone, 125 to 250 mg intravenously every 6 hours for 3 to 5 days) has been recommended as initial treatment in patients with rapidly progressive COP.

BOOP (COP)

treatment

- The therapy of choice is prednisone, 0.75 mg/kg/day with gradual tapering of dosage in the following several months
- Several day course of high-dose parenteral corticosteroid therapy may be needed in patients with rapidly progressive COP
- The usual duration of corticosteroid therapy is 6 to 12 months
- Relapse is seen in one-third of the patients if a short treatment course of less than 3 months of corticosteroid therapy is used
- Some of these patients require low-dose maintenance prednisone therapy for several years to maintain stabilization with chronic symptoms

start

with 0.75 mg/kg/day of prednisone for 4 weeks,

then

0.5 mg/kg/day for 6 weeks,

then

20 mg/day for 6 weeks,

then

5 mg/day for 6 weeks.

- 12 studies, 160 patients

59,4% complete response

26,9% partial response

13,7% non-responsiveness complete

6% fatal outcome

→ **Coexisting pulmonary fibrosis**

Davison et al Q J Med 1983

Epler et al N Engl J Med 1985

Cordier JF et al Chest 1989

Costabel U et al Chest 1992

Izumi T et al Chest 1992

Katzenstein AL et al Am J Surg Pathol 1986

Bellomo R et al Thorax 1991

Cryptogenic Organizing Pneumonia

Characteristics of Relapses in a Series of 48 Patients

ROMAIN LAZOR, ANDRÉ VANDEVENNE, ANTOINE PELLETIER, PASCAL LECLERC, ISABELLE COURT-FORTUNE, JEAN-FRANÇOIS CORDIER and the Groupe d'Etudes et de Recherche sur les Maladies "Orphelines" Pulmonaires (GERM"O"P)

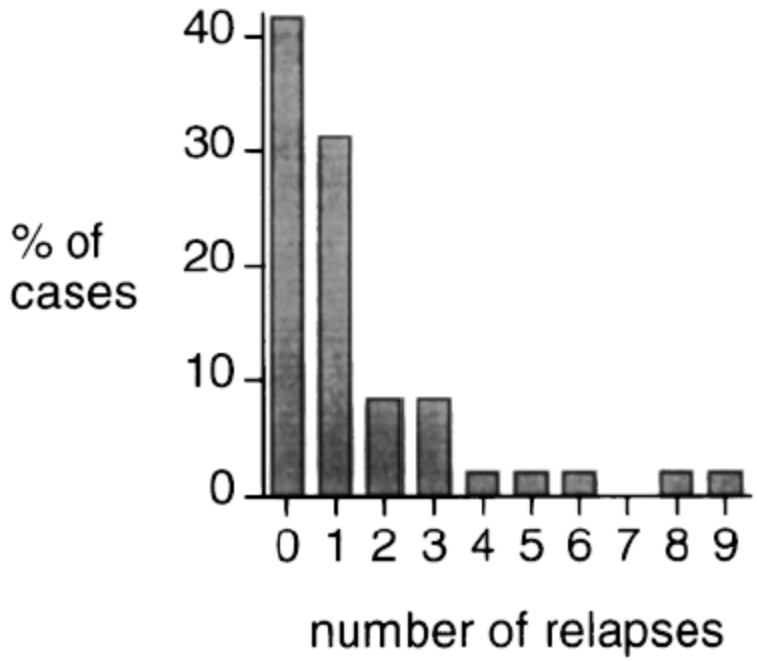

Figure 1. Distribution of 48 cases of COP according to the number of relapses. Values are expressed as percentage of the whole study population.

The occurrence of relapses in COP could be regarded as a relatively benign and acceptable phenomenon, rather than a dangerous event requiring aggressive management.

Macrolides: A Treatment Alternative for Bronchiolitis Obliterans Organizing Pneumonia?

Diane E. Stover and Debra Mangino

Chest 2005;128;3611-3617

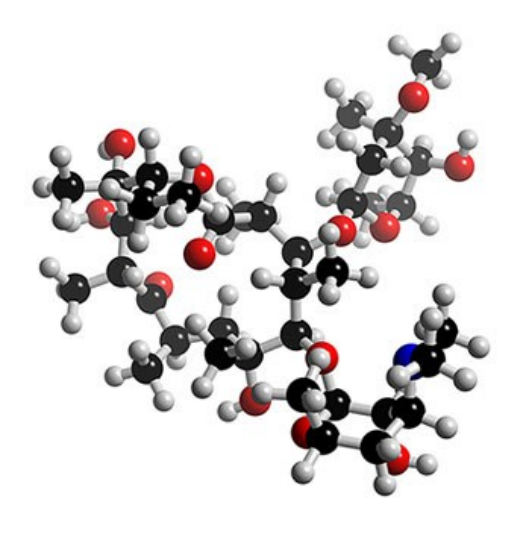

- Difffuse Panbronchiolitis
- Cystic Fibrosis
- Bronchiectasis
- Chronic Sinusitis
- Chronic otitis media
- Nasal poliposis
- Chronic Bronchitis
- COP

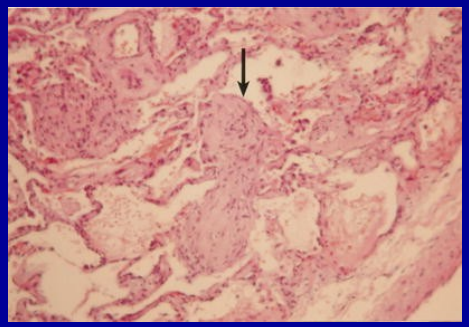

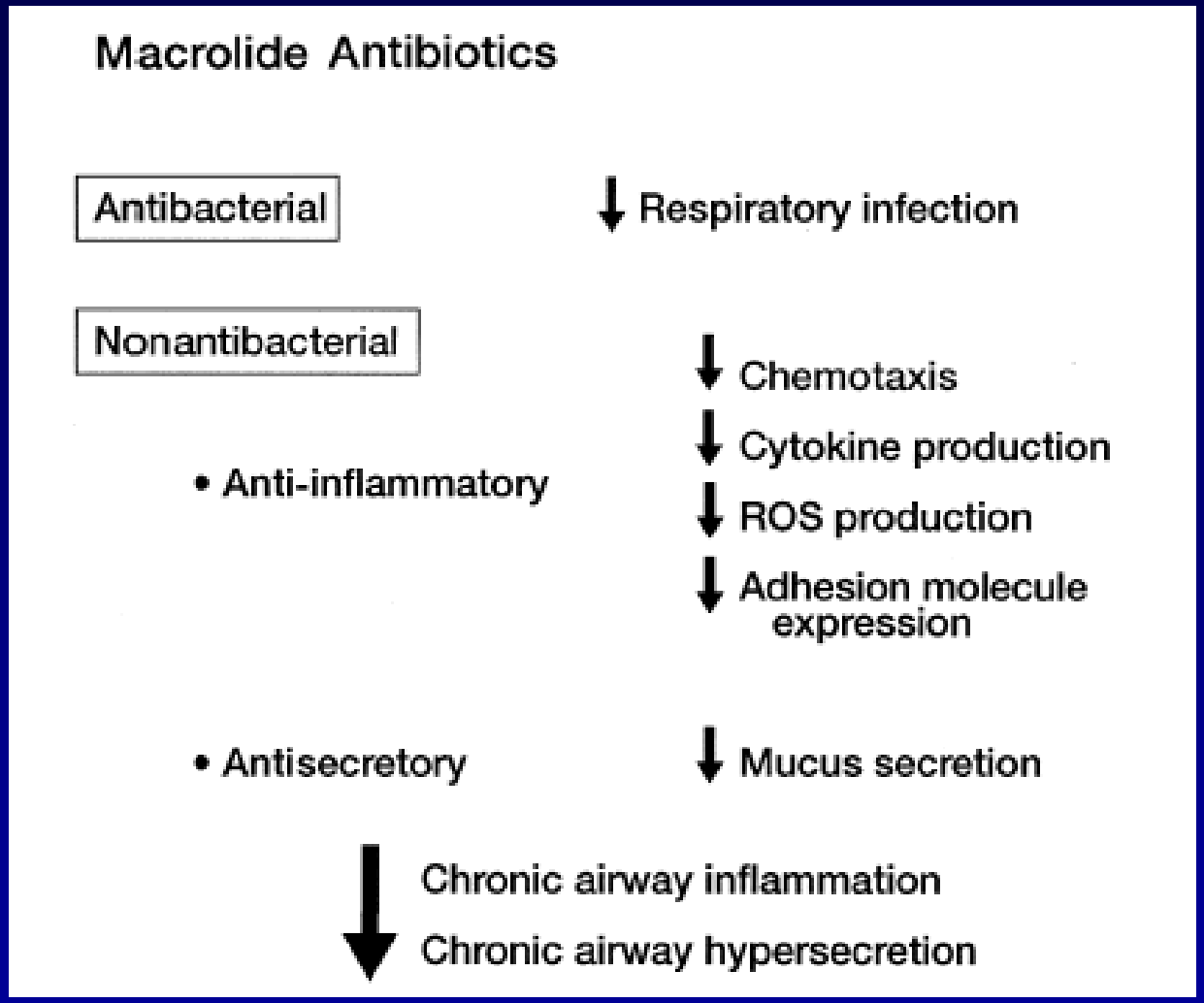

Macrolide antibiotics — A few case reports have described responses to a macrolide antibiotic (eg, clarithromycin 250-500 mg twice a day) in patients with mild symptoms

In these cases, a prolonged course of three to six months was needed;

It is thought that the benefit of the macrolide was related to anti-inflammatory rather than antimicrobial effects

More commonly, the diagnosis of COP is made after a patient has failed one or more courses of antibiotics.

Macrolides are not indicated for the vast majority of patients, but may be a second line option for patients with mild disease who are intolerant of glucocorticoids.

Stover et al Chest 2005

Prognosis

- The mortality of OP has been reported to vary from 5% to as high as 27%.

- Mortality ratesappear higher with SOP than COP.
- Corticosteroid therapy results in complete recovery in up to 80% of patients within a few weeks to 3 months. The disease is persistent in the remainder.
- The development of a reticulonodular pattern on high resolution CT is an indicator that organizing pneumonia is progressing to fibrosis.
- Cases of spontaneous disease regression have been rarely reported.

- *Relapses are common, ranging from 13% to 58%, and are usually associated with tapering or withdrawal of corticosteroid treatment.*

Summary

- First, the clinical presentation mimics pneumonia which may result in the administration of inappropriate antibiotics and a prolonged delay in diagnosis and treatment.
- Second, OP is associated with many specific causes (SOP) that may require therapy in order for the lung disease to be adequately treated.
- Third, COP is a cause of acute respiratory distress syndrome, and this would be an indication for corticosteroids which are often rapidly effective.