Πνευμονική ίνωση και Νοσήματα Συνδετικού Ιστού

«26ο Πανελλήνιο Πνευμονολογικό Συνέδριο 2017»

Αργύριος Τζουβελέκης

Πνευμονολόγος – Μαρί Κιουρί Υπότροφος European Respiratory Society

Α’ Πανεπιστημιακή Πνευμονολογική Κλινική – ΓΝΝΘΑ «Σωτηρία»

argyrios.tzouvelekis@fleming.gr

argyrios.tzouvelekis@yale.edu

Περίληψη

- Εισαγωγικά στοιχεία – Παθογένεια, Διάγνωση,Πρόγνωση
- Περιπτώσεις ασθενών
- 1) ILD-Scleroderma
- 2) ILD-Rheumatoid arthritis
- 3) ILD-PM/DM/Anti-synthetase syndrome
- 4) IPAF

Εισαγωγή

Παθογένεια

Απώλεια Ανοσιακής Ανοχής

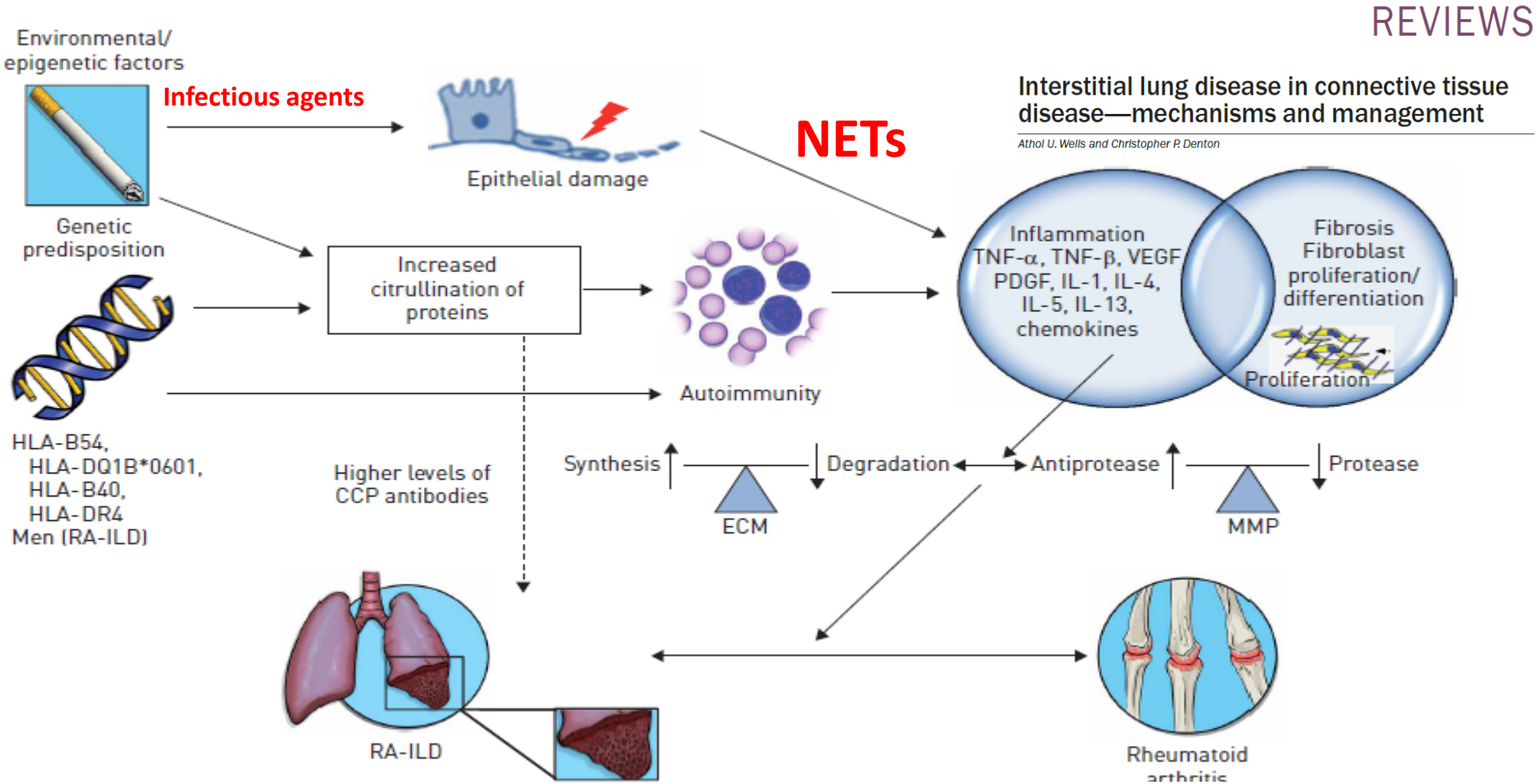

NATURE REVIEWS | RHEUMATOLOGY

Διαγνωστικά διλήμματα

Respiratory involvement in autoimmune diseases

- Pleomorphic Involvement

MAIN DIFFERENTIAL DIAGNOSES

- Rheumatic involvement?
- Drug induced respiratory involvement?
- Infection-Immunocompromise?

- «Rheumatoid lung» is not a correct diagnosis!
- 10% of cases ILD precedes CTD diagnosis!

Table 2. Respiratory involvement in CTDs

N=30

Manifestation	RA	SLE	SS	DM-PM	Sjögren's syndrome	MCTD	AS
Pleural effusion	++	++	±	–	±	+	–
Pleural fibrosis	+	–	–	–	–	–	–
Pneumothorax	+	–	–	–	±	–	+
Pneumomediastinum	–	–	–	+	–	–	–
Upper airway involvement	+	–	–	–	++	–	+
Bronchiolitis/bronchiectasis	+++	+	+	–	+	+	–/±
UIP	++	+	+	++	–/±	+	+
NSIP	+	+	+++	+++	–/±	++	+
Apical fibrobullous disease	±	–	±	–	–	±	++
LIP	–/±	–/±	–/±	–	+	–	–
Lymphoproliferative disorders	±	–	–	–	+	–	–
CPFE	+	–	±	–	–	±	±
DIP/RB-ILD	+	–	+	–	–	–	–
COP/AFOP	+	+	+	++	+	+	–
Eosinophilic pneumonia	–/±	–	–	–	–	–	–
DAD/ARDS	+	++	+	++	–	+	–
Pulmonary nodules	+	–	–	–	–	–	–
Pulmonary infections	+	+++	+	+	±	+	+
Aspiration pneumonia	–	–	++	++	–	+	±
Lung cancer	–	–	++	++	–	+	–
Pulmonary amyloidosis	–/±	–	–	–	–	–	–
PAH	+	+	++	+	–	++	±
DAH/capillaritis	–/±	+	–/±	–/±	–	±	–
Vasculitis	+	+	–	+	–	+	±
Pulmonary thromboembolism	+	++	+	±	–	+	–
Acute reversible hypoxemia	–	+	–	–	–	–	–
Respiratory muscle dysfunction	–/±	+	–	++	–	–	±
Thoracic cage involvement	±	–/±	–	±	–	–	+
Obstructive sleep apnea	±	–	–	–	–	–	++

Papiris, Bouros et al. Respiration 2015

Interstitial lung disease in connective tissue disorders

Aryeh Fischer, Roland du Bois

Lancet

Vol 380 August 18, 2012

	ILD	Airways	Pleural	Vascular	DAH
Systemic sclerosis	+++	–	–	+++	–
Rheumatoid arthritis	++	++	++	+	–
Primary Sjögren's syndrome	++	++	+	+	–
Mixed CTD	++	+	+	++	–
Polymyositis/ dermatomyositis	+++	–	–	+	–
Systemic lupus erythematosus	+	+	+++	+	++

The signs show prevalence of each manifestation (–=no prevalence; +=low prevalence; ++=medium prevalence; +++=high prevalence). ILD=interstitial lung disease. DAH=diffuse alveolar haemorrhage. CTD=connective tissue disease.

Table 1: **CTDs and common pulmonary manifestations**

ILD patterns in autoimmune diseases

TYPE	SSc	RA	PM/DMM	SLE	MCTD	Sjögren's
UIP	++	++	++	++	+	-
NSIP						++ 25%
OP						-
DAD						_
DIP						+/-
LIP	_	_	_	_	_	+++ 20%
DAH / CAPILARITIS	+	+	+	+++	_	_
ILD	+++	++	+++	+	++	+

CPFE and CTDs – 10%
Younger male (57yrs) , smokers
More common in RA and SSc
Lower emphysema score
Preserved lung volumes- ⇓DLCO

Cottin et al. Arthritis Rheum 2011; 63: 295

Slide courtesy of D.Bouros

Airway involvement in autoimmune diseases

	Rheumatoid arthritis	SLE	DM/PM	Sjögren´s
Bronchitis	++			+
Bronchiectasis	++			±
Follicular bronchiolitis	±			±
Oblit. bronchiolitis	+	±	±	
BOOP/OP	++	±	++	±

Shaw et al. Eur Respir Rev 2015

Methotrexate Pneumonitis

- Prevalence 0.3-7.5%, > 120 cases in literature
- Mostly subacute (progress in weeks), acute, and chronic course also possible
- Cough, dyspnea, fever
- Blood: eosinophilia in 20%
- X-ray: interstitial and interstitial/alveolar
- BALF: mostly CD4 lymphocytosis

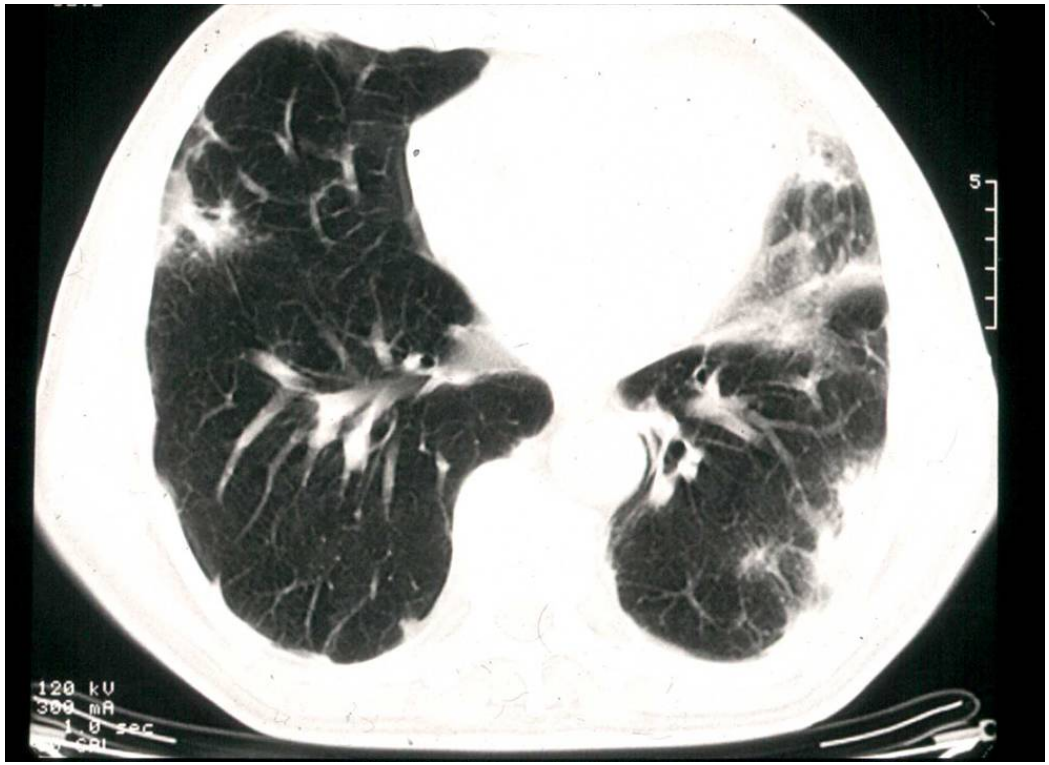

Imokawa et al. Eur Respir J 2000; 15: 373

Diagnostic algorithm of CTD-ILD

Clinical	Radiology	Pathology
• History • Physical • Laboratory • PFTs	• Chest X-ray • HRCT	• Surgical lung biopsy

Primary care physicians	Pulmonologists Rheumatologist	Pulmonary Radiologists	Pulmonary Pathologists

Multidimensional and multidisciplinary

GOLD STANDARD

Ρόλος του ανοσολογικού ελέγχου

Serology defines patterns of lung involvement

	RA	SLE	Scleroderma	DM-PM	Sjögren's syndrome	MCTD
Immunofluorescence nuclear pattern						
Homogeneous		+				
Speckled		+	+	+	+	+
Peripheral		+	+			
Nucleolar			+	+		
Specific nuclear antigens targeted in CTDs						
dsDNA		+				
ssDNA		+				
Histones		+				
Sm		+				
U1-RNP		+	+ (PH)			
U3-RNP			+ (ILD, PH)			
U11-RNP			+ (ILD)			
U12-RNP			+ (ILD)			
rRNP		+				
RNP	+	+	+			+
SSA/Ro		+ (ILD)		+ (ILD)	+	
SSB/La		+			+	
Ku		+	+	+ (PH)		
Ki		+				
Scl-70			+ (ILD)			
CENP A-E			+ (PH)			
Th/To			+ (ILD, PH)			
RNA-pol-1			+			
RNA-pol-2			+			
RNA-pol-3			+			
Jo-1 (cytoplasmic)				+ (ILD)		
EJ (cytoplasmic)				+ (ILD)		
OJ (cytoplasmic)				+ (ILD)		
PL-7 (cytoplasmic)				+ (ILD)		
PL-12 (cytoplasmic)				+ (ILD)		
KS (cytoplasmic)				+ (ILD)		
Zo (cytoplasmic)				+ (ILD)		
YRS (cytoplasmic)				+ (ILD)		
Mi-2 (cytoplasmic)				+		
SRP				+		
CADM-140 (MDA5)				+ (AIP)		
PM-Scl			+	+		
Non-ANA autoantibodies						
ANCA						
RF	+					
ACPA	+ (↑ILD)					

Διάγνωση και παρακολούθηση

Initial evaluation and monitoring of CTD-ILD

1. Evaluation of dyspnea and cough
2. Respiratory function evaluation

Spirometry, lung volumes, diffusion *(FVC, FEV_1, TLC, TLco)*-

- Arterial blood gases-SaO_2,
- Six minute walking distance test (6 MWDT)

1. HRCT
2. BAL in case of abnormal HRCT
3. Assess comorbid conditions (PH, lung cancer, OSA)
4. Alert on acute respiratory events (DAH, infections, RF)

Follow-up of CTD-ILD

1. Clinical evaluation
2. Respiratory function evaluation (3-6 mos and yearly)
3. Significant deterioration:
   1. FVC >10% (-3.0% to 3.0%-Clinically meaningful)*
   2. TLco >15%
   3. 6MWT >50 m (24m-MCID**)
4. Low dose HRCT – treat them as high risk for ILD-cancer

❖ *SCL-70 (+) patients have higher risk.*

AJRCCM 2008;177:1248–1254

**Reliability of FVC in SLS-I-II studies-AJRCCM 2017;in press*
*** duBois et al- AJRCCM 2011*

Πρόγνωση

Prognosis of CTD-ILD

Patients with CTD-related ILD survive longer than those with idiopathic ILD

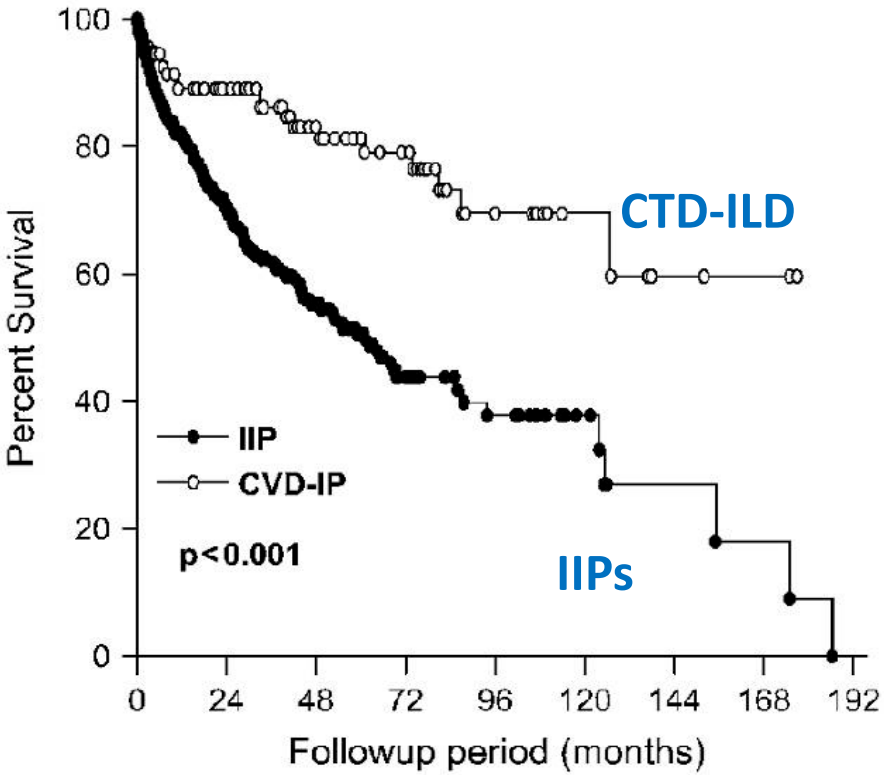

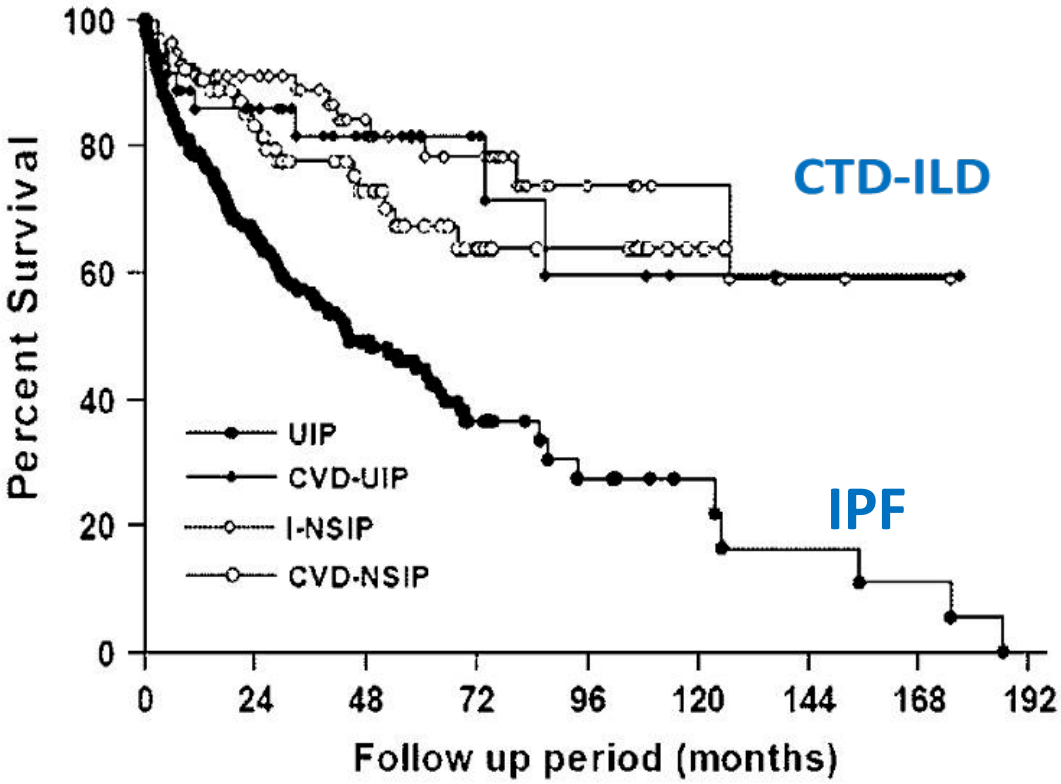

Park JH et al, Am J Respir Crit Care Med 2007

Περιπτώσεις ασθενών

40-yrs old, female, non-smoker, DOE (mMRC II/IV)+fatigue the past 9 months – GERD symptoms, medical Hx: unremarkable, Raynaud:+ Velcro type crackles: +

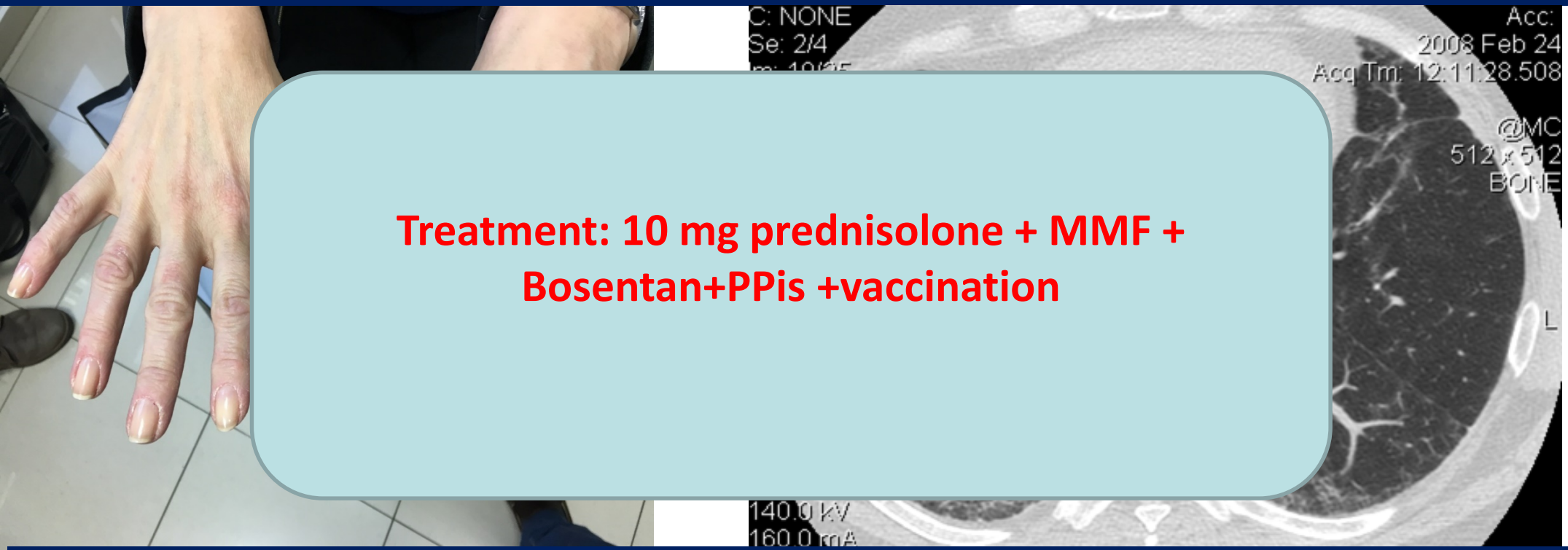

Treatment: 10 mg prednisolone + MMF + Bosentan+PPis +vaccination

BAL: 24%L,N:13% (-) AFB, (-) fungi,
FVC: 70%, TIF: 86, TLC: 69%, DLCO: 45%
RVSP: 65 mmHg, Serology: ANA: 1/640, antiScl-70: +
GI endoscopy: esophagitis

Προγνωστικοί Δείκτες

1. Demographic –baseline data (race, age, comorbidities-PH)
2. Functional status (FVC, DLCO) (during 3 yrs follow-up)
3. Radiological extent (>20% involvement – HRCT)
4. Histopathological subset (fNSIP, UIP)
5. BAL (eosinophilia)

Bouros et al. Am J Respir Crit Care Med. 2002
Goh NS, et al. Am J Respir Crit Care Med. 2008

Θεραπεία

- Tre … se
  co
- MI … study
  …e)
- GE
- Tre … esults
- Co … F
- Future – anti-fibrotic Rx (pirfenidone – nintedanib)

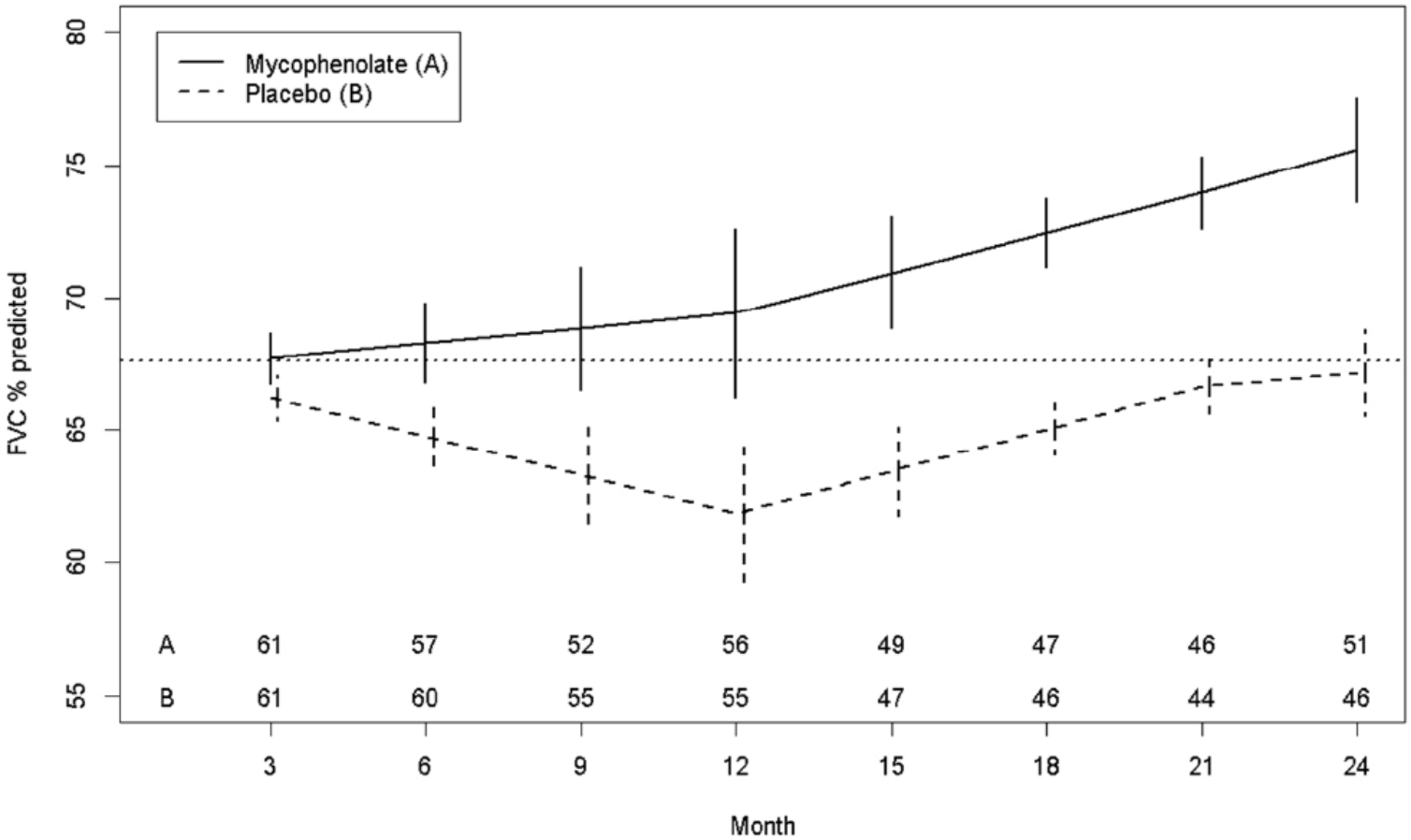

Tashkin et al. SLS-1-NEJM 2006. Cyclophosphamide superior to placebo.
Tashkin et al. SLS-2. Lancet RM 2016. Cyclophosphamide = MMF. MMF more tolerant

72-yr old, female, non-smoker, dry cough+DOE (mMRC II/IV) the past 24 months
–Morning stiffness, arthralgia past 3 years
Coronary Heart disease, arterial hypertension, hyperlipidemia
Velcro type crackles +

Treatment: 5 mg prednisolone + vaccination + enrollment in anti-fibrotic protocols (pirfenidone or nintedanib)

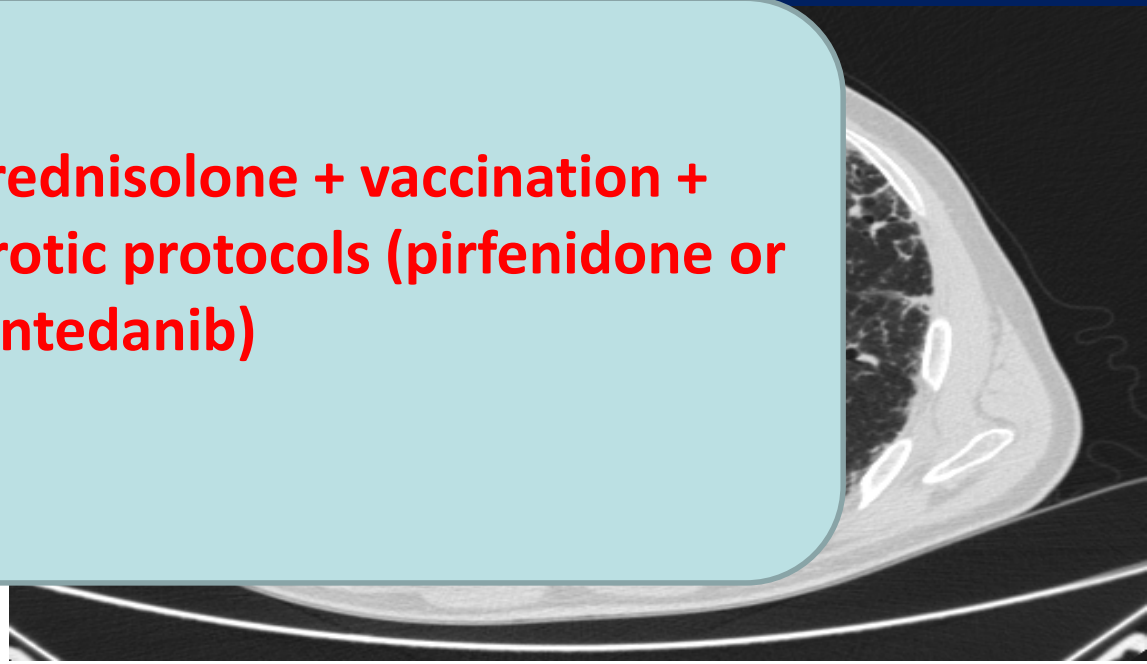

BAL: 28%L,N:13% (-) AFB, (-) fungi,
FVC: 68%, TIF: 73, TLC: 63%, DLCO: 35%
RVSP: 35 mmHg, Serology: ANA: 1/160, RF: 165U/ml, anti-CCPs: 18 (3x)

33 yrs old female, smoker, history of RA since 17 yrs old under CS+MTX
acute onset dyspnea + chest pain

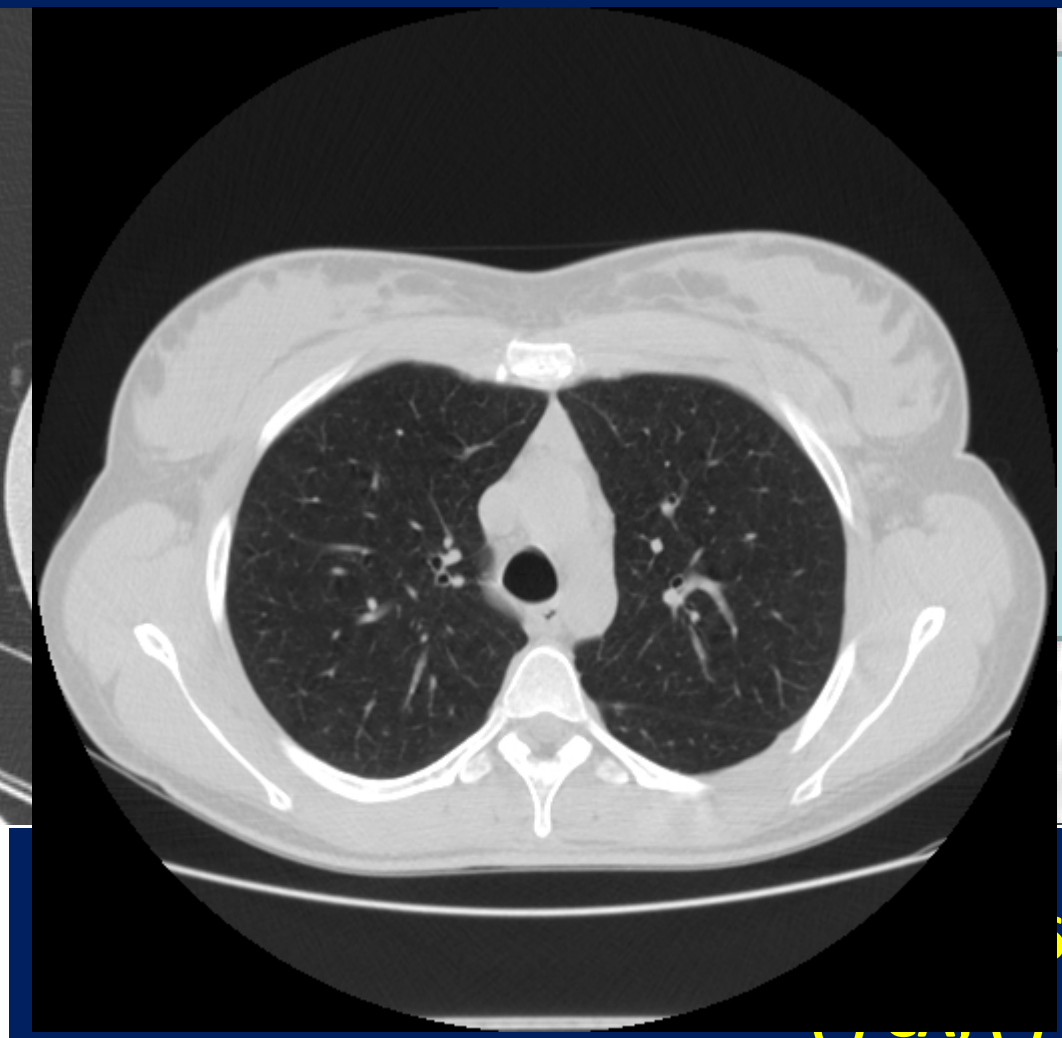

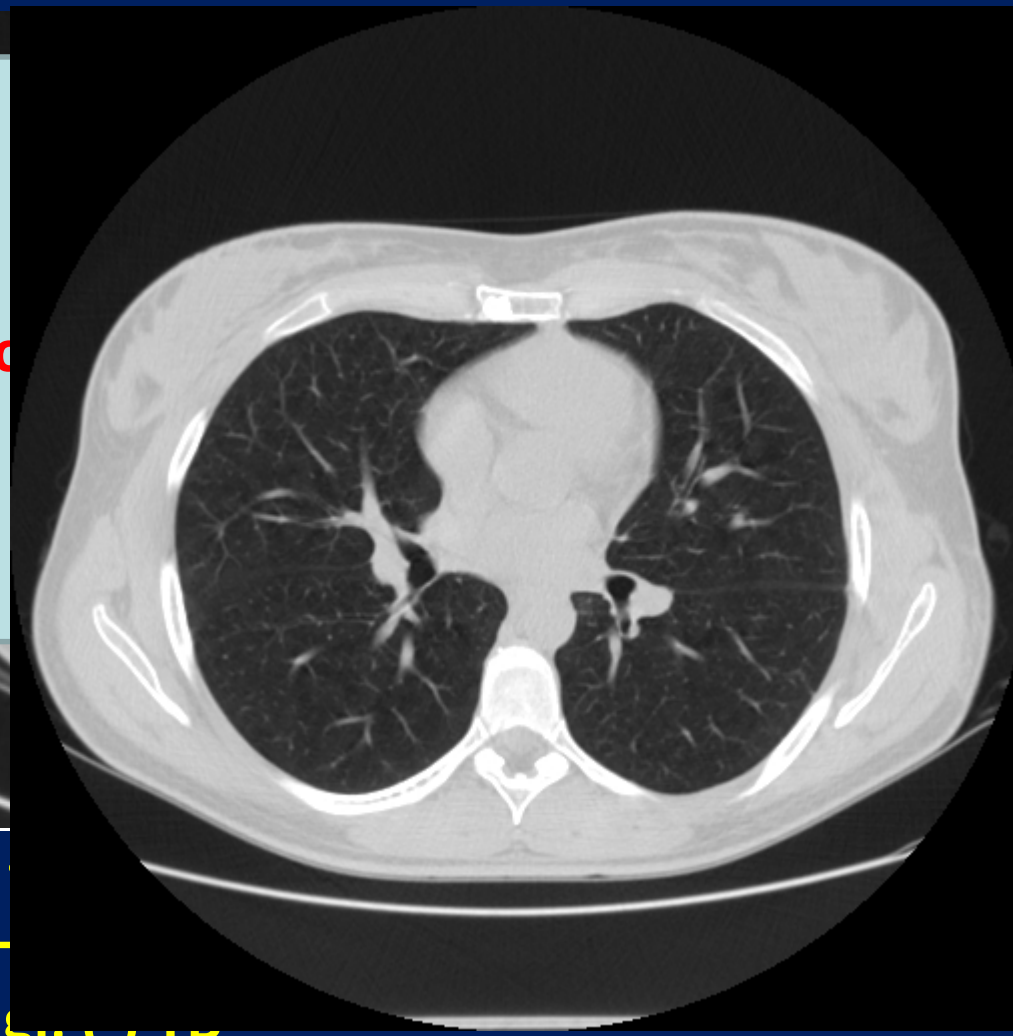

(Toc

ngi

ια –

fung.) ( ) TB

FVC: 70%, TIF: 76, TLC: 68%, DLCO: 68%

Θεραπεία – Παρακολούθηση

- MTX-cornerstone of RA (10mg/wk) – MTX-ILD??
- Corticosteroids (low doses – 10-15 mg prednisolone)
- MMF – good for maintenance Rx
- Biological agents in REFRACTORY cases- Rituximab or anti-IL6 (LITHE study) – Beware of Immunocompromise!!
- Anti-TNFa: no improvement –potentially hazardous
- Smoking cessation
- LTOT - Influenza Vaccination – Antibiotics if needed
- PFTs/3 mo, HRCT/6-12 mo- RA-risk of lung cancer

Shaw et al. RA-ILD. Eur Respir Rev 2015
Fischer et al. MMF in RA-ILD. J Rheum 2013

47 yrs old female, non-smoker, DOE (II/IV), dry cough-mild fever-recurrent RTIs past 12 months treated with BDs-antibiotics-mild myalgia-left shoulder-history unremarkable – Velcro type crackles +

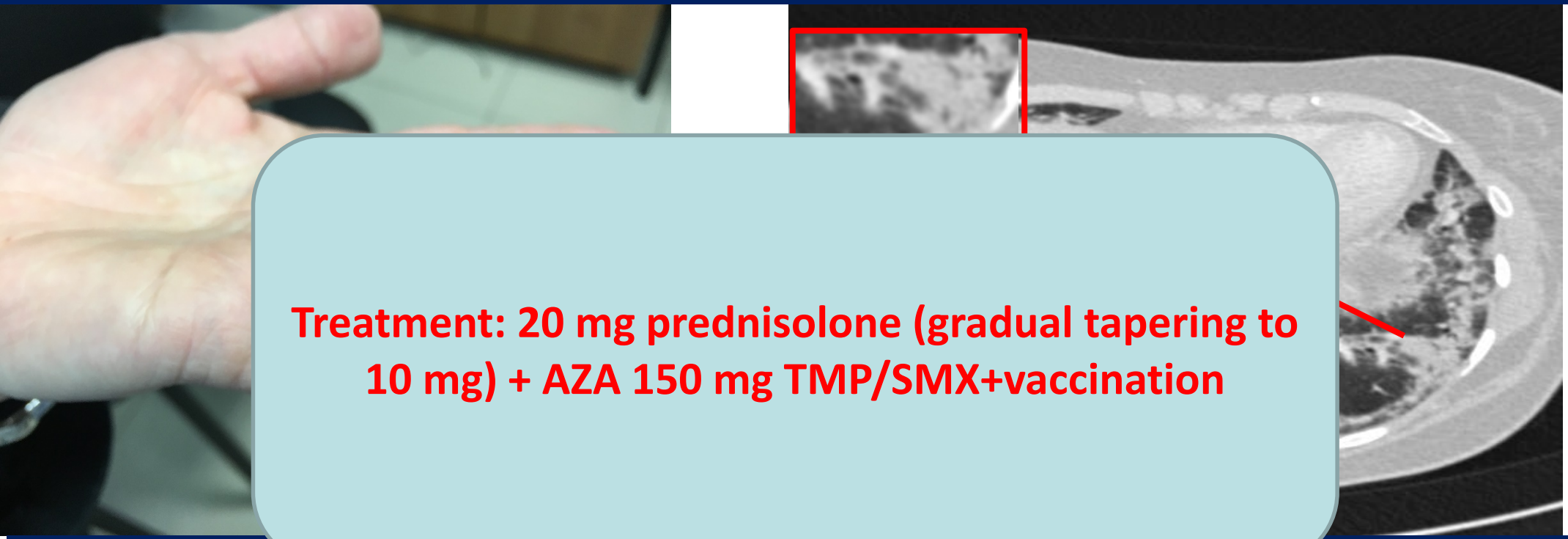

Treatment: 20 mg prednisolone (gradual tapering to 10 mg) + AZA 150 mg TMP/SMX+vaccination

ESR: 95mm/h, CPK: 55mg/dl, aldolase: 10 mg/dl

BAL: 30%L, (-) AFB, (-) fungi

FVC: 70%, TIF: 86, TLC: 69%, DLCO: 70%

6MWD: 400 m, 98%-92%

ANA: 1/640, ENA panel: (-), anti-Jo1: (-), anti-PL7: (++)

Polymyositis–Dermatomyositis-associated Interstitial Lung Disease 75% of cases

WILLIAM W. DOUGLAS, HENRY D. TAZELAAR, THOMAS E. HARTMAN, ROBERT P. HARTMAN, PAUL A. DECKER, DARRELL R. SCHROEDER, and JAY H. RYU

Division of Pulmonary and Critical Care Medicine, Division of Anatomic Pathology, Department of Diagnostic Radiology, and Section of Biostatistics, Mayo Clinic, Rochester, Minnesota

Am J Respir Crit Care Med Vol 164. pp 1182–1185, 2001

IMAGING FINDINGS

Finding	Frequency	Bilateral (%)	Lower Lobe Predominant (%)
Chest radiographs			
Irregular linear opacities	54/57 (95%)	98	93
Consolidation	14/57 (25%)	79	100
Honeycombing	2/57 (4%)	100	100
Pleural effusion	2/57 (4%)	50	NA*
Computed tomography of the lungs			
Irregular linear opacities	19/30 (63%)	100	68
Consolidation	16/30 (53%)	100	81
Ground glass opacities	13/30 (43%)	100	31
Pleural effusion	6/30 (20%)	67	NA
Honeycombing	0/30 (0%)	NA	NA

NSIP-DM= good prognosis

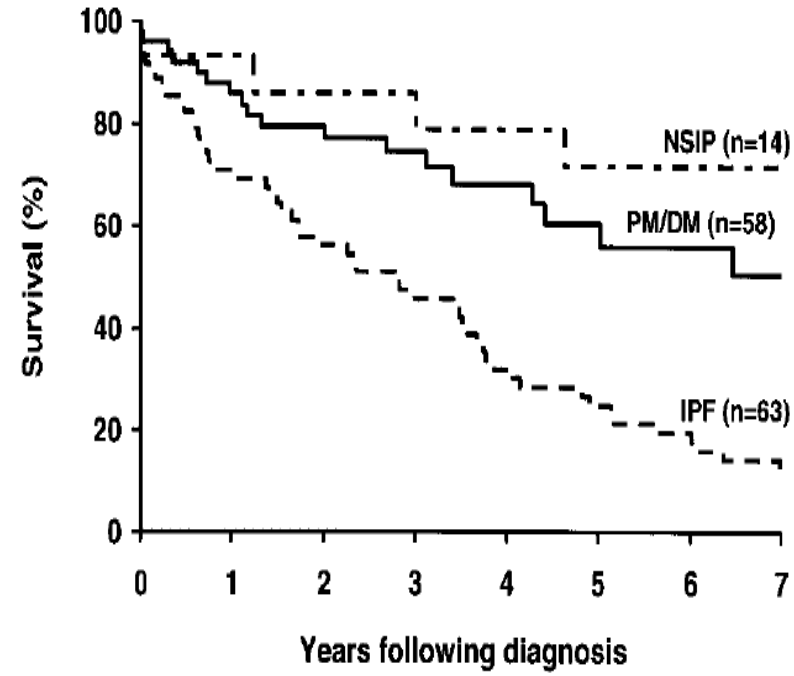

Θεραπεία

- Moderate-to-high doses of corticosteroids (0.5-0.75 mg/kg) – TMP/SMX chemoprophylaxis for PCJ (>15mg/day for >20days) (G6PD evaluation)
- Steroid sparing agents: AZA (100-150 mg), MTX (drug-induced ILD?), colchicine, cyclosporine
- Cyclophosphamide – Rituximab: pulses – in progressive ILD – Attention to acute events – AFOP, DAD, infections, respiratory muscle involvement – Respiratory failure
- Monitoring: CPK, PFTs (3 mo), HRCT: 6 mo – Risk for cancer

Shinohara. Intern Med 1997
Bunch. Ann Intern Med 1997
Sauty. Eur Respir J. 1997

60 yrs old male, ex-smoker, history of hypercalciuria, hashimoto, Non-productive cough, DOE (II/IV) last 6 mo, low-grade fever last 3 days – family doctor – moxifloxacin (WBCs: 17450, CRP: 3.4)- ? Raynaud, no arthralgia-myalgia

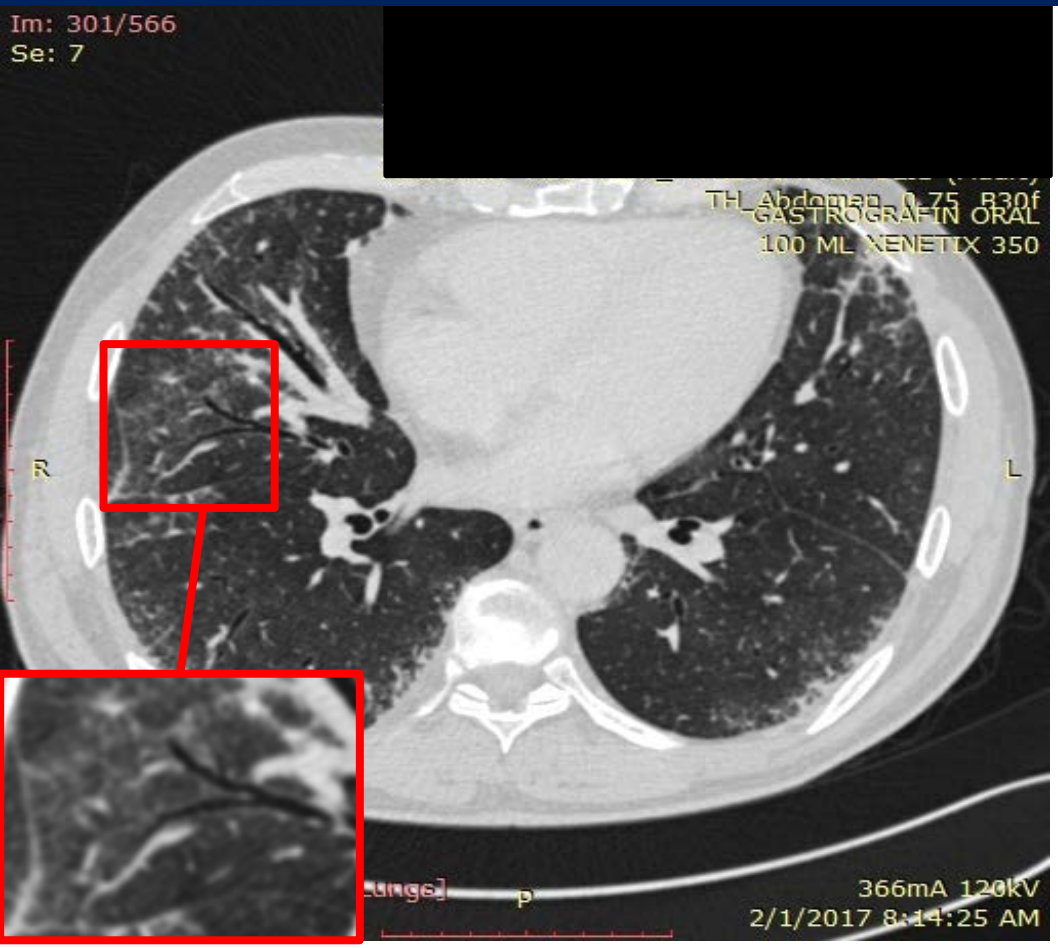

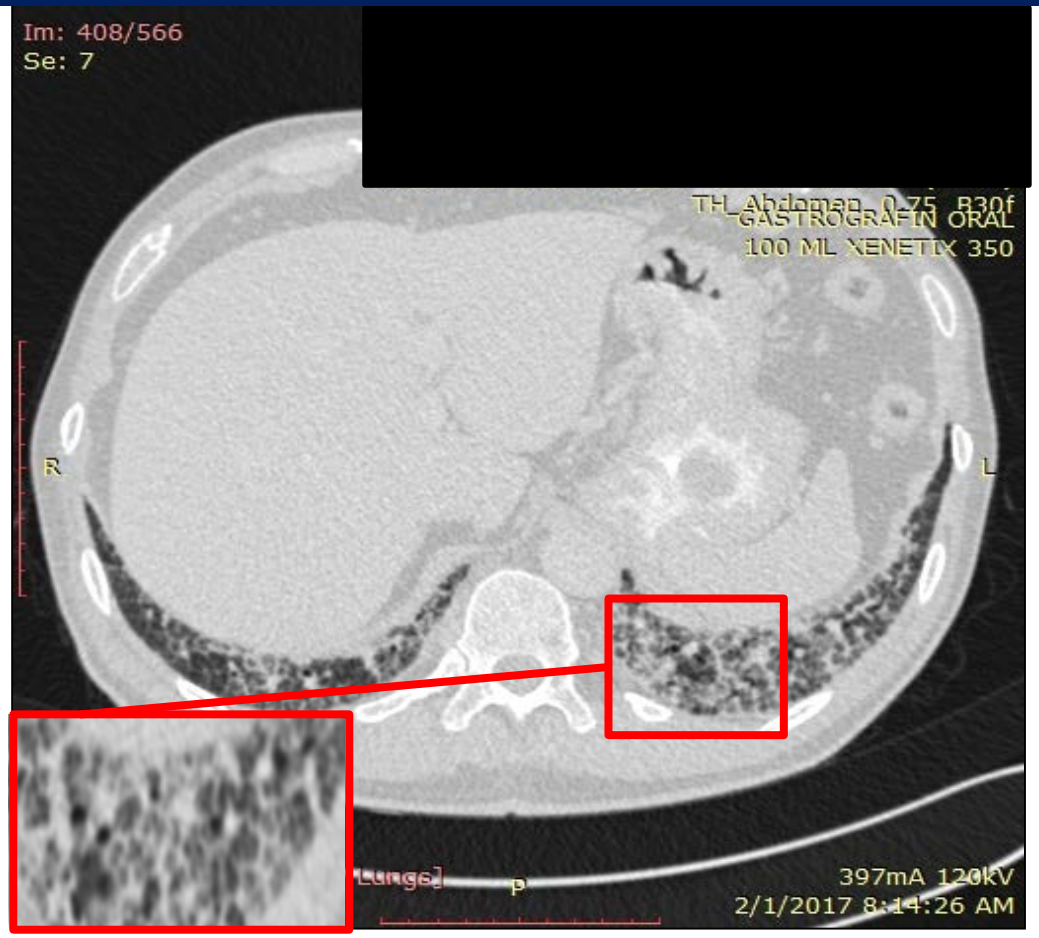

BAL: 37%L, (-) AFB, (-) fungi

ANA: 1/640, ENA panel: (-), RF: (-), FVC: 73%, Tif: 81.6, TLC: 48%, DLCO:39%

RVSP: 25 mmHg, 6MWD: 410 m, SaO2: 98% – 88%

VATS biopsy: fibrosing OP

IPAF/Unclassifiable ILD

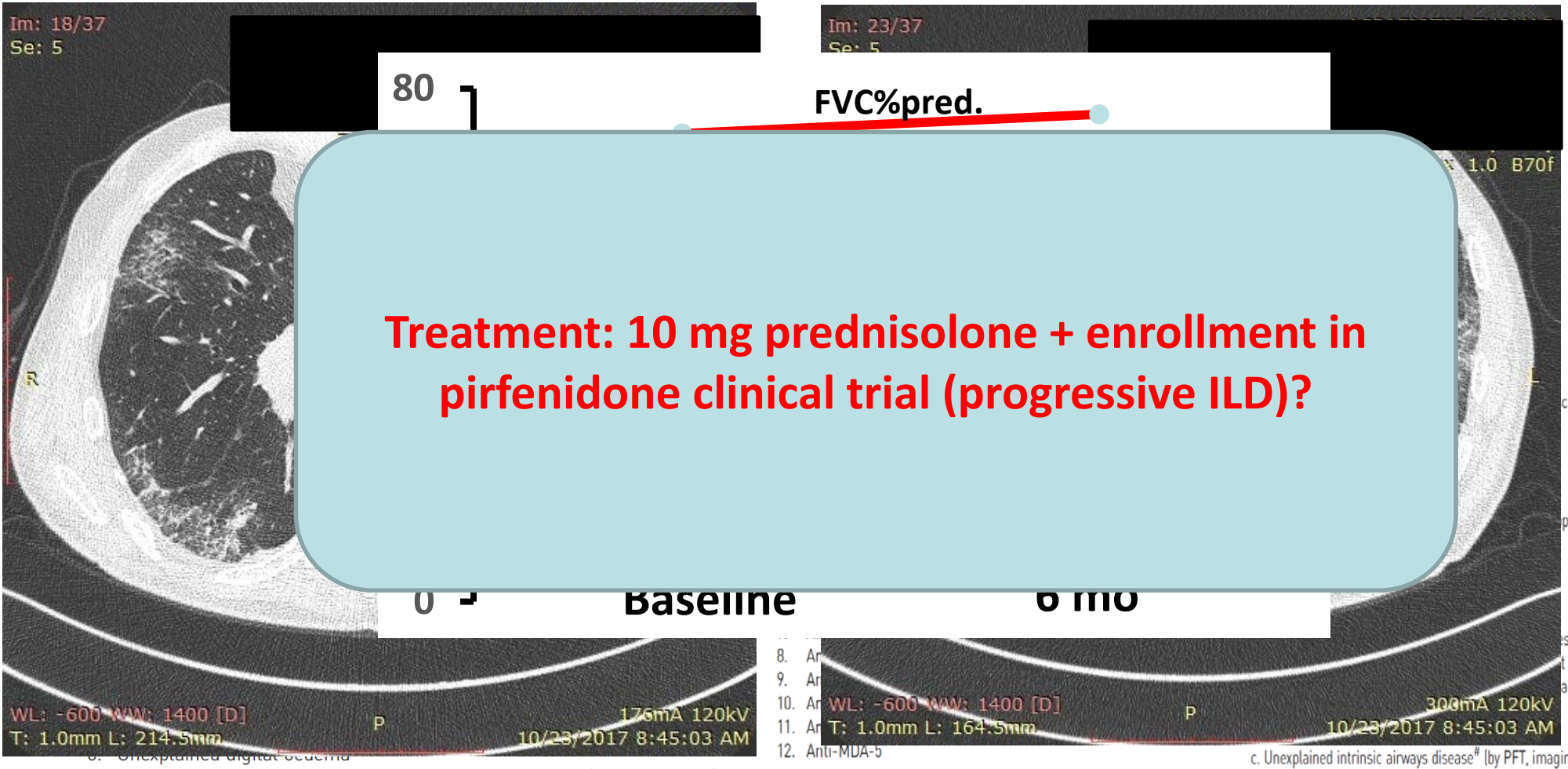

Treatment: 10 mg prednisolone + enrollment in pirfenidone clinical trial (progressive ILD)?

7. Unexplained fixed rash on the digital extensor surfaces (Gottron's sign)

8. An
9. An
10. An
11. An
12. Anti-MDA-5

c. Unexplained intrinsic airways disease# (by PFT, imaging or pathology)
d. Unexplained pulmonary vasculopathy

TAKE HOME MESSAGES

- All CTDs – Lung interstitium involvement
- CS + Immunomodulation (MMF*) –RTX in refractory cases
- Do not immunocompromise the patients
- Avoid meaningless treatment in stable disease
- Regular routine evaluation – Lung cancer
- Need for biomarkers and RCTs
- Consider comorbidities and acute respiratory events

**Volkmann et a- MMF versus placebo in SSc-Arthritis and Rheum-2017*
Fischer et al. MMF in RA-ILD. J Rheum 2013

Sublata causa tollitur effectus

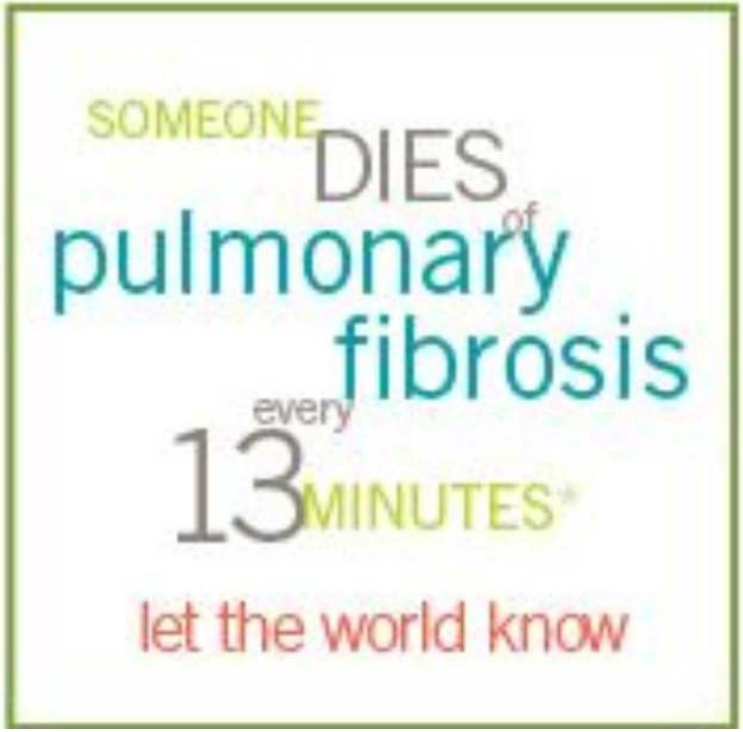

Ευχαριστώ

NATURE REVIEWS | RHEUMATOLOGY

REVIEWS

Interstitial lung disease in connective tissue disease—mechanisms and management

Athol U. Wells and Christopher P. Denton

thebmj

STATE OF THE ART REVIEW

Management of interstitial lung disease associated with connective tissue disease

Stephen C Mathai, Sonye K Danoff

CrossMark
click for updates