# ΠΝΕΥΜΟΝΙΤΙΣ ΑΠΟ ΥΠΕΡΕΥΑΙΣΘΗΣΙΑ

**ΔΗΜΟΣΘΕΝΗΣ ΜΠΟΥΡΟΣ MD, PhD, FERS, FAPSR, FCCP**
**ΚΑΘΗΓΗΤΗΣ ΠΝΕΥΜΟΝΟΛΟΓΙΑΣ ΕΚΠΑ,**
**ΜΟΝΑΔΑ ΔΙΑΜΕΣΩΝ ΝΟΣΗΜΑΤΩΝ ΝΝΘΑ**

dbouros@med.uoa.gr, debouros@gmail.com

# Conflicts of Interest

I declare

NO conflicts of interest

# ΟΡΙΣΜΟΣ

**Η πνευμονίτιδα από υπερευαισθησία** ***Hypersensitivity pneumonitis (HP),*** **ή εξωγενής αλλεργική κυψελιδίτιδα** ***(extrinsic allergic alveolitis)*****, είναι πολύπλοκο σύνδρομο που ποικίλει σε ένταση, κλινική παρουσίαση και πορεία, και είναι απότοκο διεγερμένης ανοσολογικής απάντησης σε μεγάλη ποικιλία οργανικών σωματιδίων.**

- **Μπορεί να καταλήξει σε *πνεύμονα τελικού σταδίου και θάνατο.***

# Estimated Relative Distribution of Specific ILDs in the US

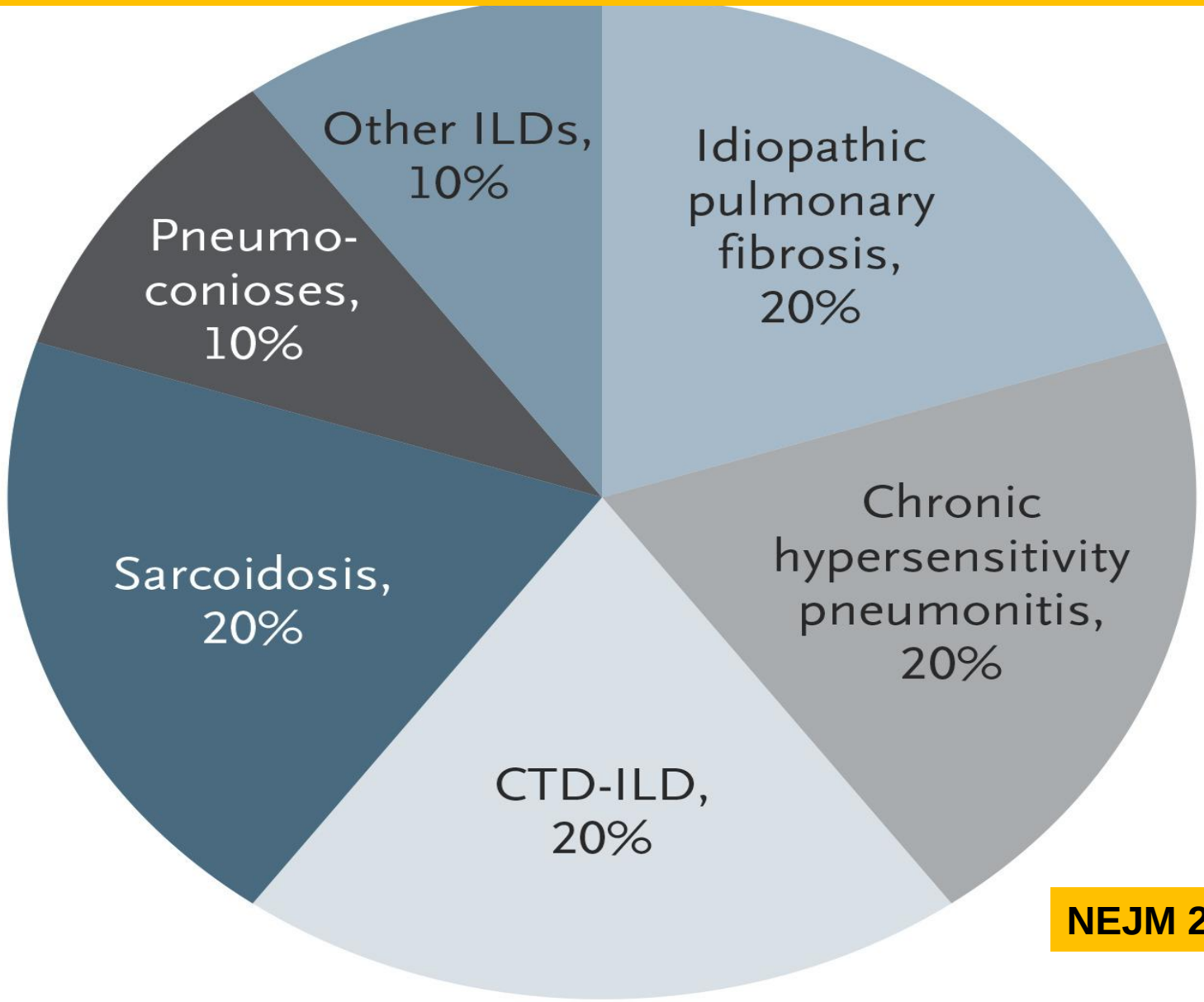


NEJM 2018

# ΑΙΤΙΟΛΟΓΙΑ ΤΗΣ HP

**>300 αερογενή αντιγόνα, όπως:**

- ***αγροτική σκόνη***
- ***bioaerosols,***
- ***Μικροοργανισμοί (fungal, bacterial, or protozoal),***
- ***ανόργανα χημικά***
- ***φάρμακα***

THE
FINE
BEDDING
COMPANY
Goose Feather
& Down Duvet

© Alamy

# Health Benefits of Hot Tubs

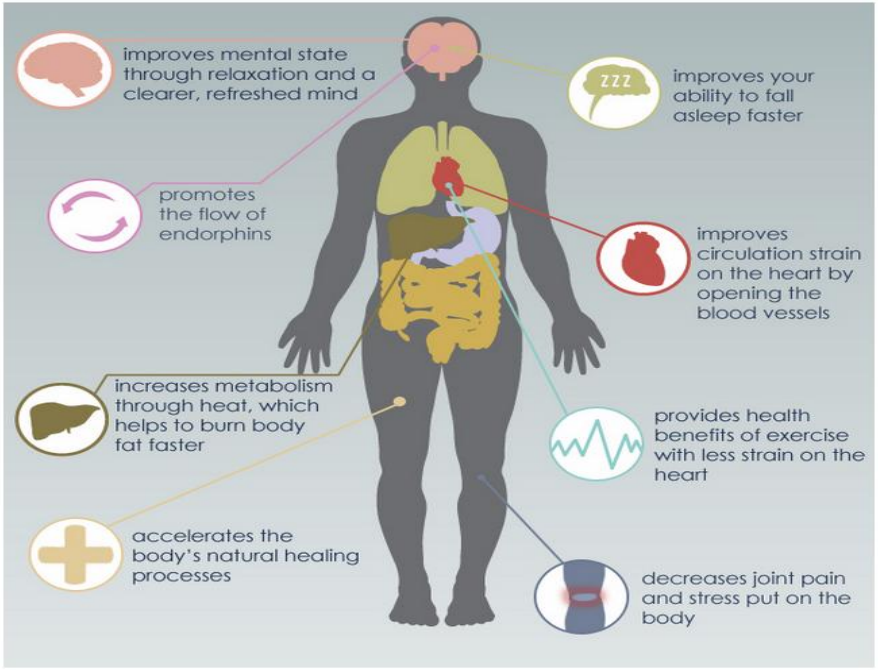




## Hot-tub dome

Hot tubs and whirlpools might use less energy if they were covered with this 14-ft.-dia. plastic dome. Its 10 side panels and four top panels are formed of ⅛-in.-thick Uvex. Solarium, Inc. (2901 John, Troy, Mich. 48084) makes the free-standing structure.

# HISTORY EVALUATION

- **“Εάν μη έλπηται, ανέλπιστον ουκ εξευρήσει, ανεξερεύνητον εόν και άπορον.”**

- **“Εάν δεν ελπίζεις, δεν θα βρεις το ανέλπιστο, γιατί είναι ανεξερεύνητο και απρόσιτο.”**

**Ηράκλειτος**

# ΠΑΘΟΓΕΝΕΙΑ ΤΗΣ HP

- **Υπόθεση διπλής προσβολής (two-hit hypothesis):**
- **1η προσβολή: γενετική ευαισθησία *(genetic susceptibility)* ή περιβαλλοντικοί παράγοντες που αυξάνουν τον κίνδυνο εκδήλωσης της HP μετά την**
- **2η προσβολή: έκθεση στο αντιγόνο.**

Selman M et al. AJRCCM 2012

# PATHOGENESIS OF HP

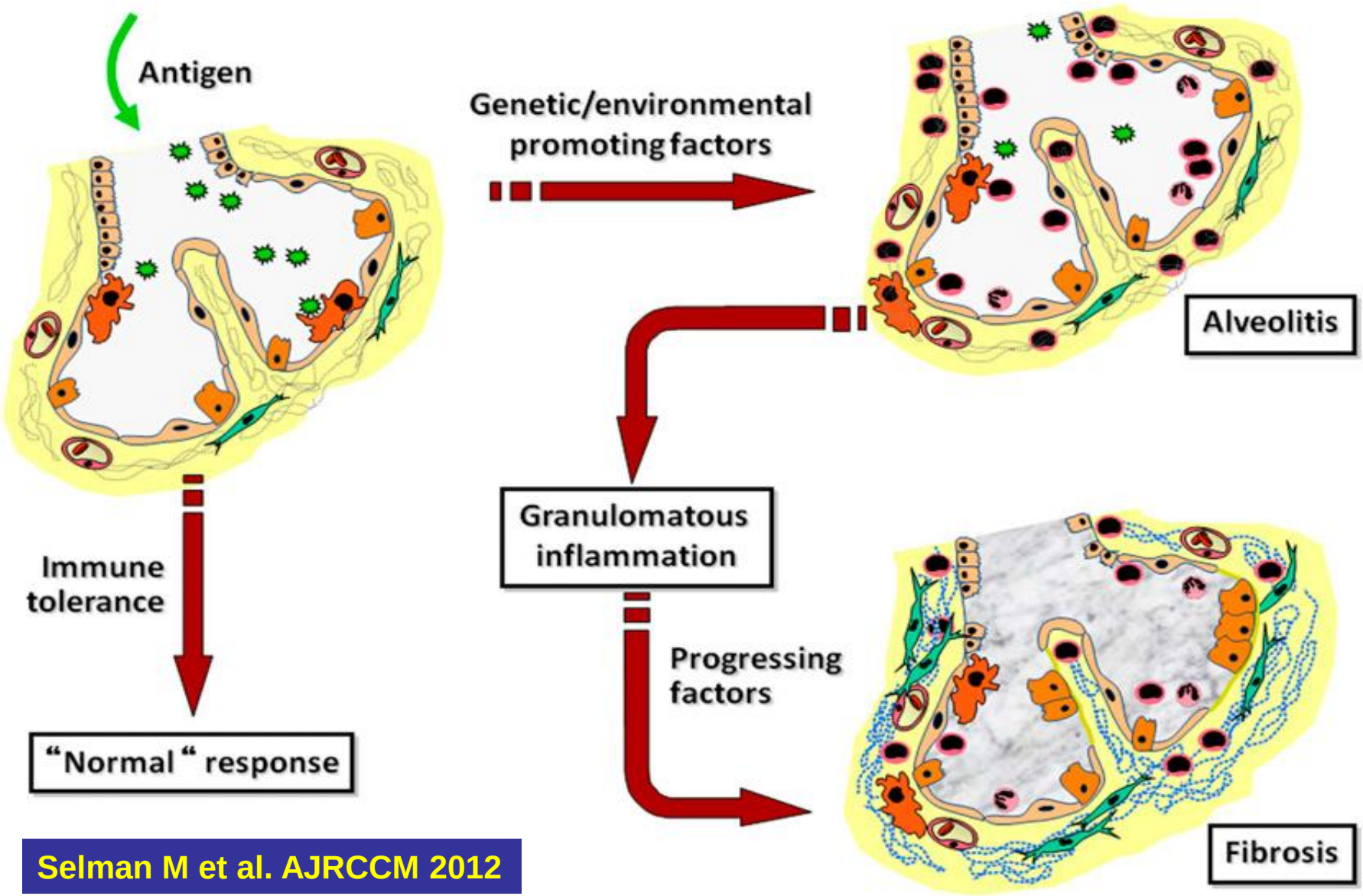


Selman M et al. AJRCCM 2012

# HP PATHOGENESIS

- Immunopathogenesis in 3 phases
- Only 5-10% of exposed develop HP
- Most have normal harmless IgG response
- Recent RTI can precipitate the pathological process

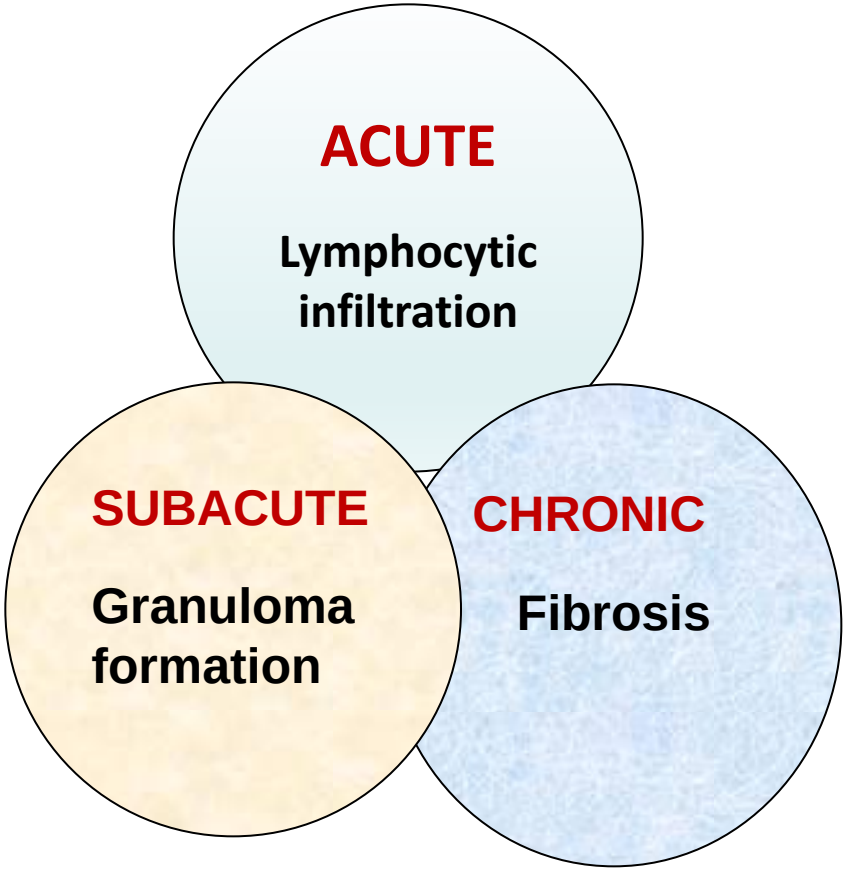

# Τελοεισπνευστικοί λεπτοί μη μουσικοί ρόγχοι στις βάσεις + κριγμοί (squeaks*).




Προκαλούνται από την απότομη διάνοιξη από τον εισπνεόμενο αέρα, των μικρών βρόγχων, που τα τοιχώματά τους έχουν αποφραχθεί από οίδημα, ενώ στους μεγάλους βρόγχους οφείλονται στη ρήξη πολύ ξηρών, παχύρρευστων φυσαλίδων.

* a short, very high cry or sound

# Telomeropathy in Chronic Hypersensitivity Pneumonitis

**Am J Respir Crit Care Med. 2019 Nov 1;200(9):1086-1087.**

Demosthenes Bouros, MD, PhD, Argyrios Tzouvelekis, MD, PhD,

**Rare Protein-Altering Telomere-related Gene Variants in Patients with Chronic Hypersensitivity Pneumonitis.**

**16 of 144 patients (11.1%) in the discovery cohort and 17 of 209 patients (8.1%) in the replication cohort.**

**[Am J Respir Crit Care Med. 2019, *Nov 1;200( 9):1154-1163***

# ΠΟΤΕ ΘΑ ΥΠΟΠΤΕΥΘΟΥΜΕ ΔΠΠ

**ΕΝΑ ΑΠΟ ΤΗΝ ΣΤΗΛΗ Α ΚΑΙ ΕΝΑ ΑΠΟ ΤΗΝ ΣΤΗΛΗ Β**

| Column A | Column B |
| --- | --- |
| ΔΥΣΠΝΟΙΑ ΣΤΗΝ ΚΟΠΩΣΗ | ΠΑΘΟΛΟΓΙΚΗ Α/ΦΙΑ |
| ΜΗ ΠΑΡΑΓΩΓΙΚΟΣ ΒΗΧΑΣ | ΤΕΛΟΕΙΣΠΝΕΥΣΤΙΚΟΙ ΜΜΡ |
| ΟΙΚΟΓΕΙΑΚΟ ΙΣΤΟΡΙΚΟ ΔΠΠ | ΑΠΟΚΟΡΕΣΜΟΣ ΣΤΗΝ ΑΣΚΗΣΗ |
| | ΜΕΙΩΜΕΝΗ FVC *Η* $DL_{CO}$ |

# What are the features of an HRCT?

- Type of HRCT
  - Non contrast
- Resolution
  - 1 mm Slices
  - High-Resolution Reconstruction Algorithm
- View
  - Axial
  - Coronal
- Position
  - (Prone)
  - Supine
- Breathing
  - Inspiratory
  - Expiratory

(ATS/ERS/JRS/ALAT 2018)

# HRCT ΟΞΕΙΑΣ ΦΑΣΕΩΣ HP

- **Βλάβες δίκην γαλακτοχρόου υάλου (GGO).**
- **Παγίδευση αέρα *(air-trapping)* *σε δευτερογενή λοβίδια*.**
- **HRCT σε εκπνοή είναι πολύ χρήσιμη!**

- *Courtesy of Paul Stark, MD.*

# HRCT ΥΠΟΞΕΙΑΣ ΦΑΣΕΩΣ HP

- **Πολλαπλά βοτρυδιακά οζίδια (acinar nodules) *(<5mm)* σε όλο τον πνεύμονα.**

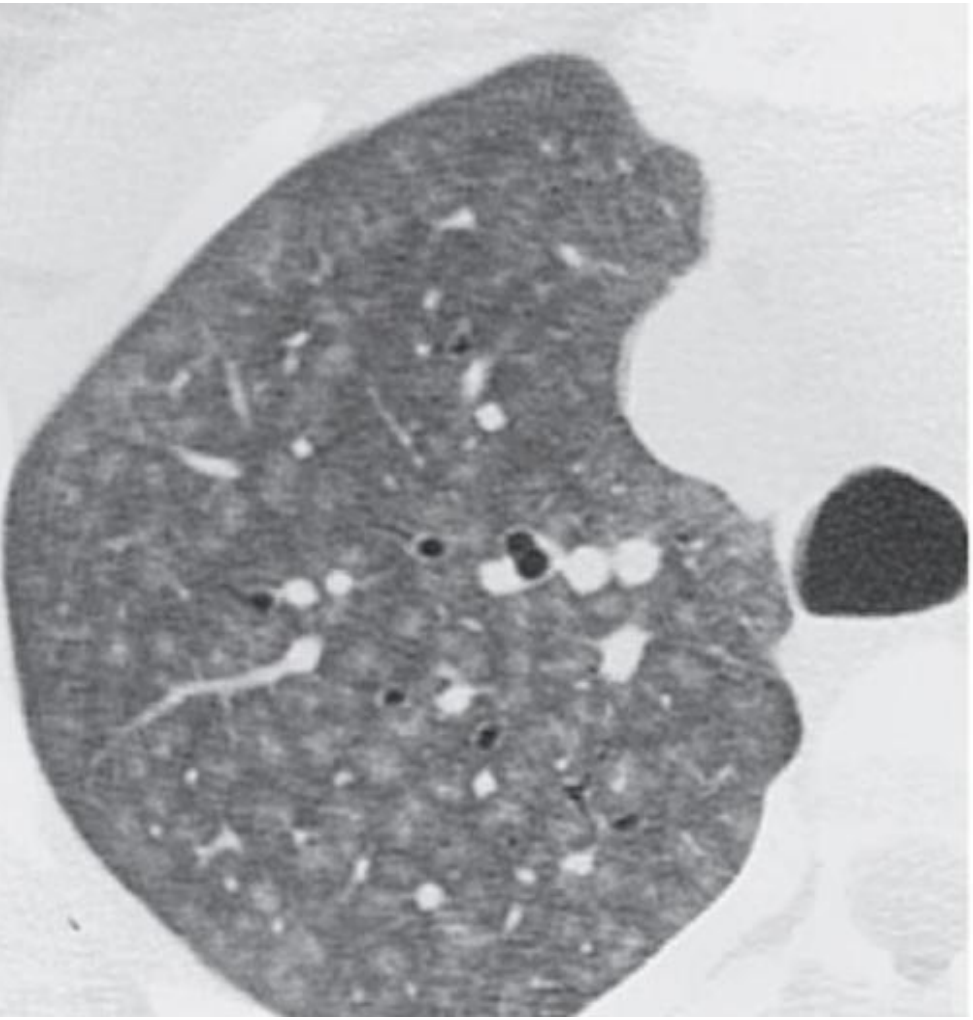

# HRCT ΧΡΟΝΙΑΣ ΦΑΣΕΩΣ HP

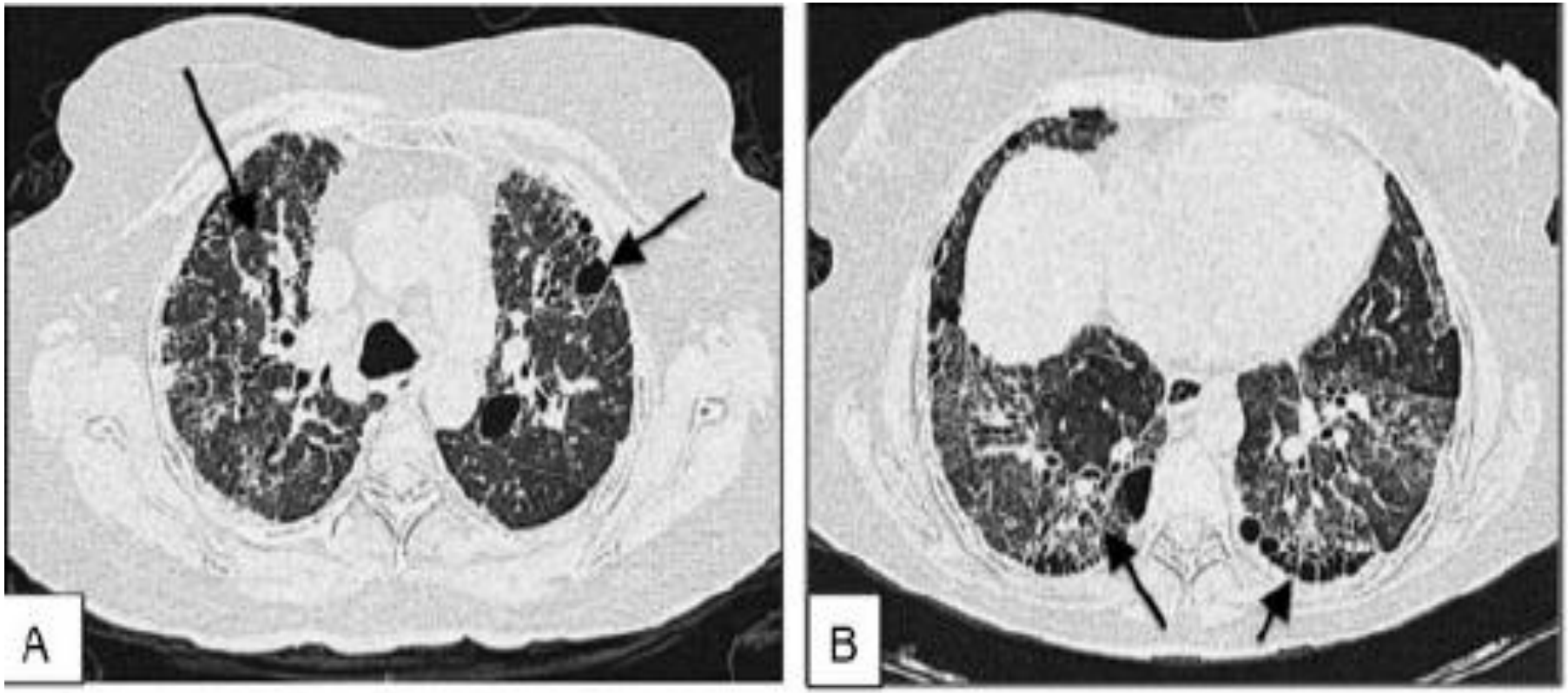


- **Εικόνα UIP (εκτεταμένες δικτυωτές σκιάσεις, βρογχεκτασίες εξ έλξεως και κηρήθρα).**
- ***Selman and Buendia-Roldan. Sem Respir Crit Care Med 2012***

HRCT 45χρονου γεωργού, μη καπνιστού, με δύσπνοια III/IV, και ξηρό βήχα από εξαμήνου, με πληκροδακτυλία, MMP (Velcro)+ κριγμούς (squeaks). BALF Λ=40%.

# Honeycombing + “head and cheese sign”

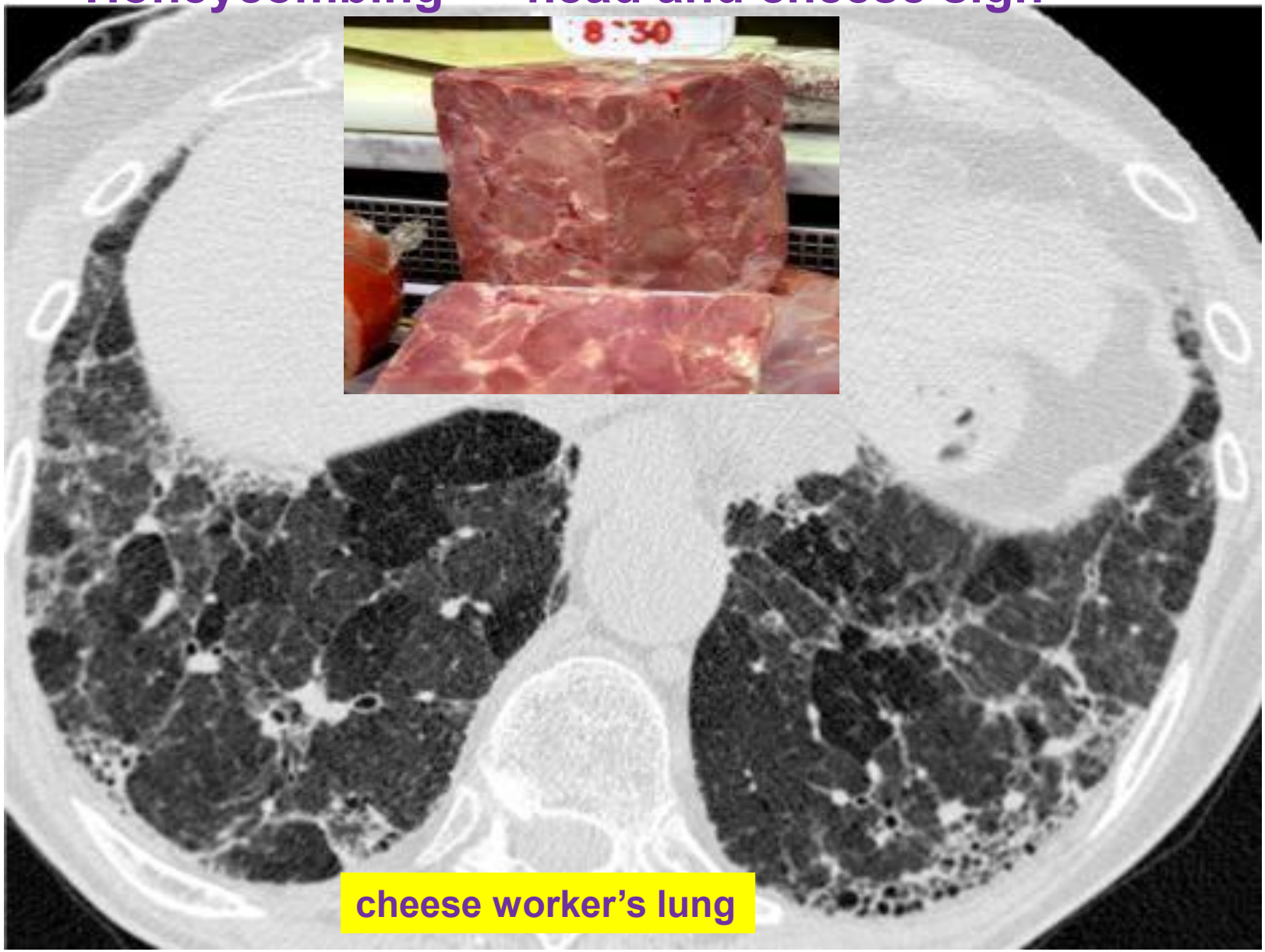

# Upper lobe predominant honeycombing

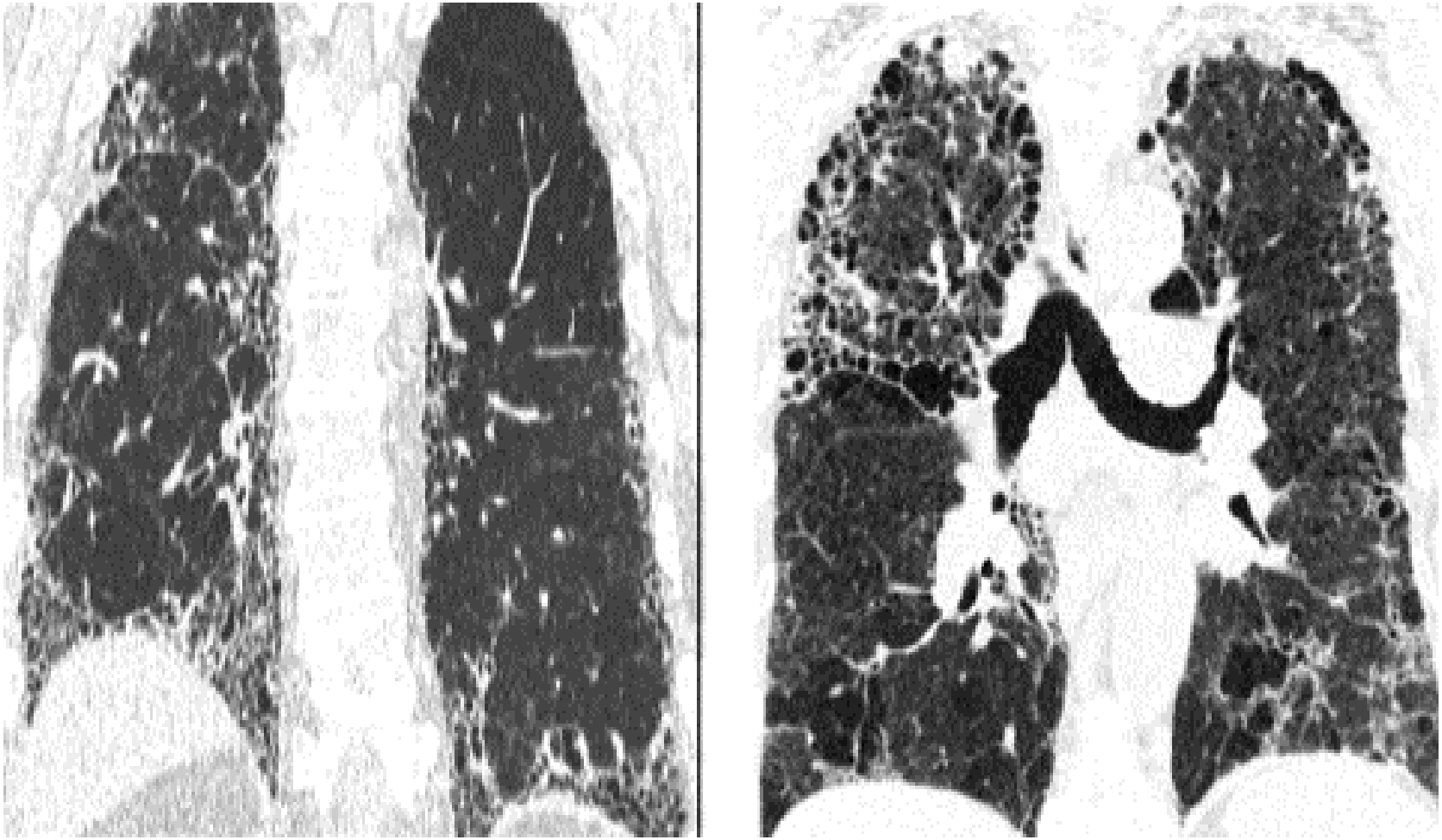

# HRCT in HP

- ✓ The presence of mosaic attenuation was present in 51% of IPF patients
- ✓ The "headcheese sign" is a highly specific radiologic finding for fibrotic HP

Barnett J, et al. ERJ 2019

# Hypersensitivity Pneumonitis

## Radiologic Phenotypes Are Associated With Distinct Survival Time and Pulmonary Function Trajectory

*Margaret L. Salisbury, MD; Tian Gu, MS; Susan Murray, ScD; Barry H. Gross, MD; Aamer Chughtai, MBBS; Mohamed Sayyouh, MBBCh; Ella A. Kazerooni, MD; Jeffrey L. Myers, MD; Amir Lagstein, MD; Kristine E. Konopka, MD;*

**CHEST 2019**

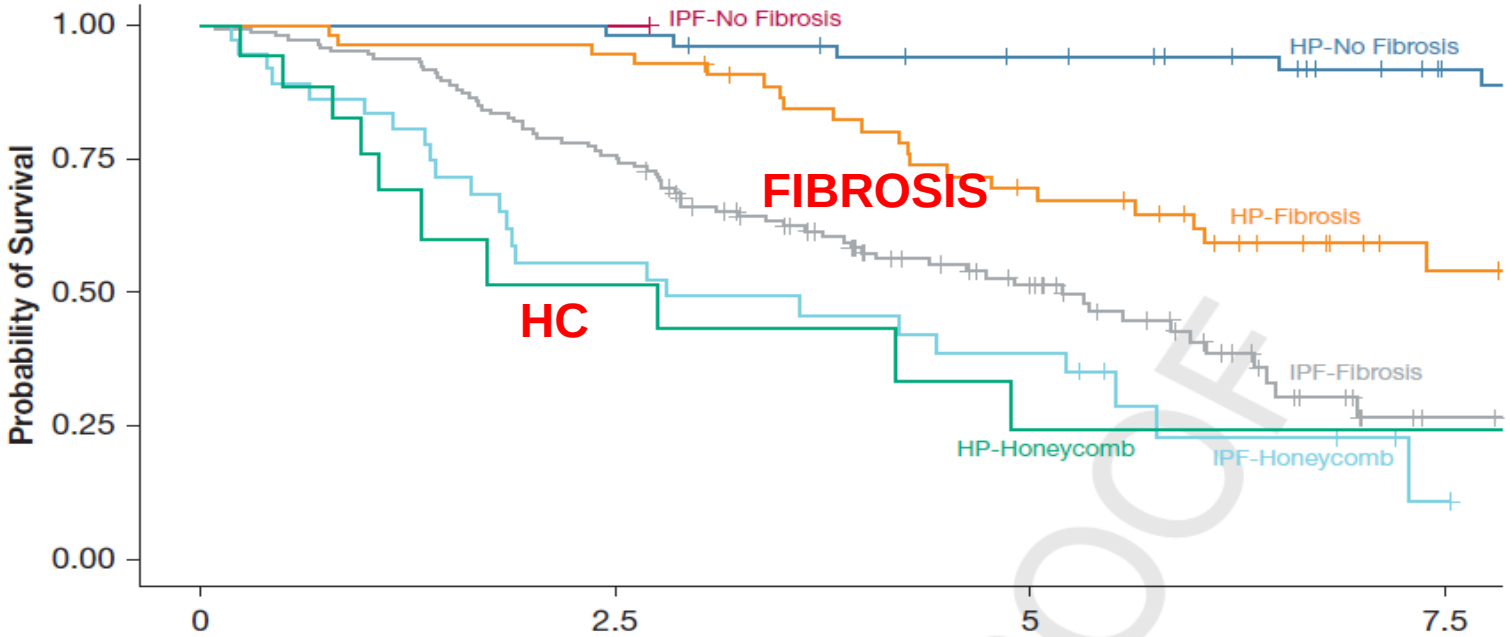


No. at risk at each time point (time in years)

| | | | | |
|---|---|---|---|---|
| IPF-No Fibrosis | 1 | 1 | 0 | 0 |
| HP-No Fibrosis | 60 | 59 | 53 | 41 |
| IPF-Fibrosis | 122 | 89 | 40 | 5 |
| HP-Fibrosis | 45 | 42 | 27 | 11 |
| IPF-Honeycomb | 29 | 14 | 9 | 1 |
| HP-Honeycomb | 12 | 5 | 2 | 2 |

# Patients with HP without radiologic fibrosis have significant increase in FVC %, whereas all other groups had a significant decrease

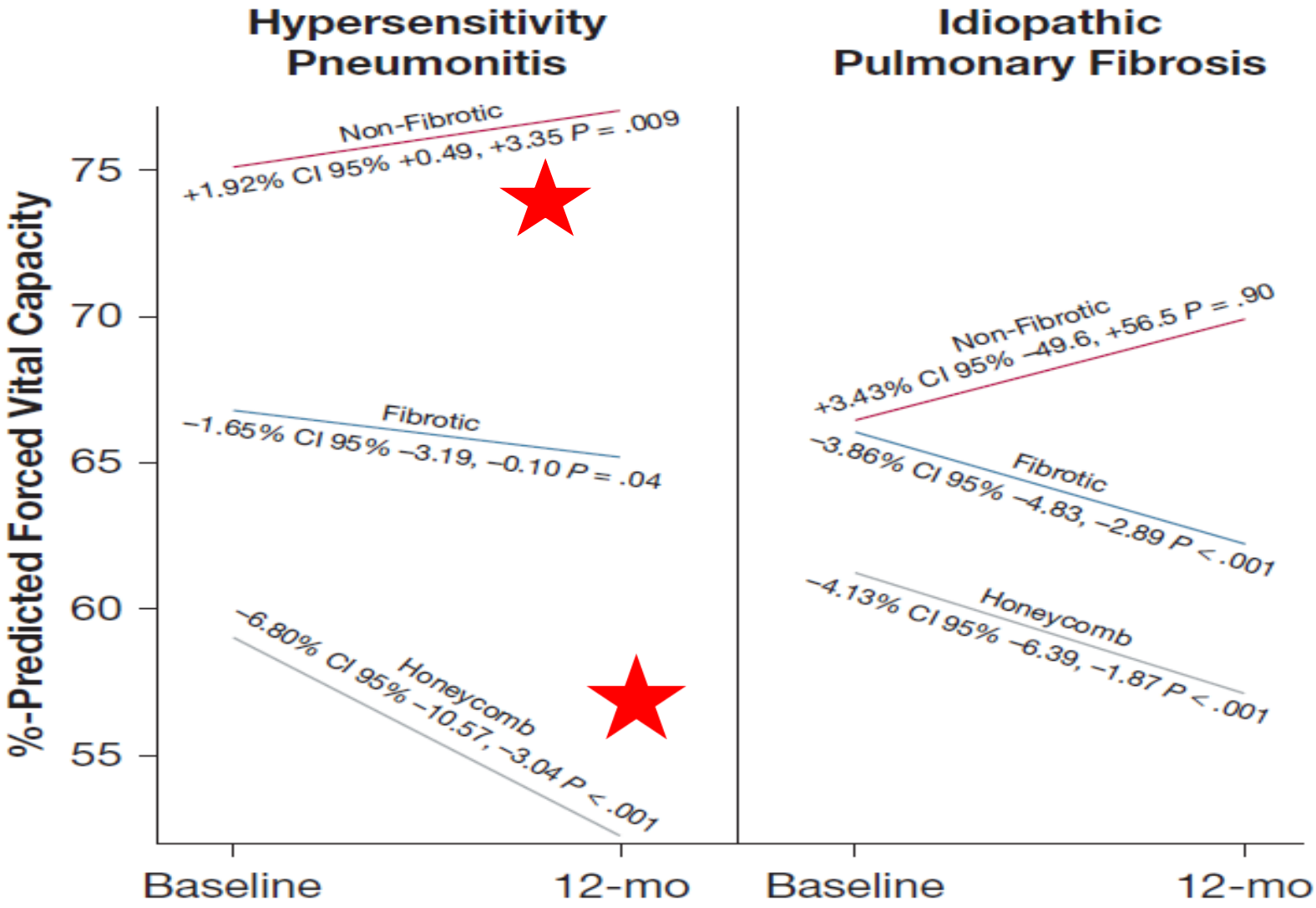

# ΕΠΙΚΑΛΥΨΗ ΧΡΟΝΙΩΝ ΙΝΩΤΙΚΩΝ ΠΝΕΥΜΟΝΟΠΑΘΕΙΩΝ

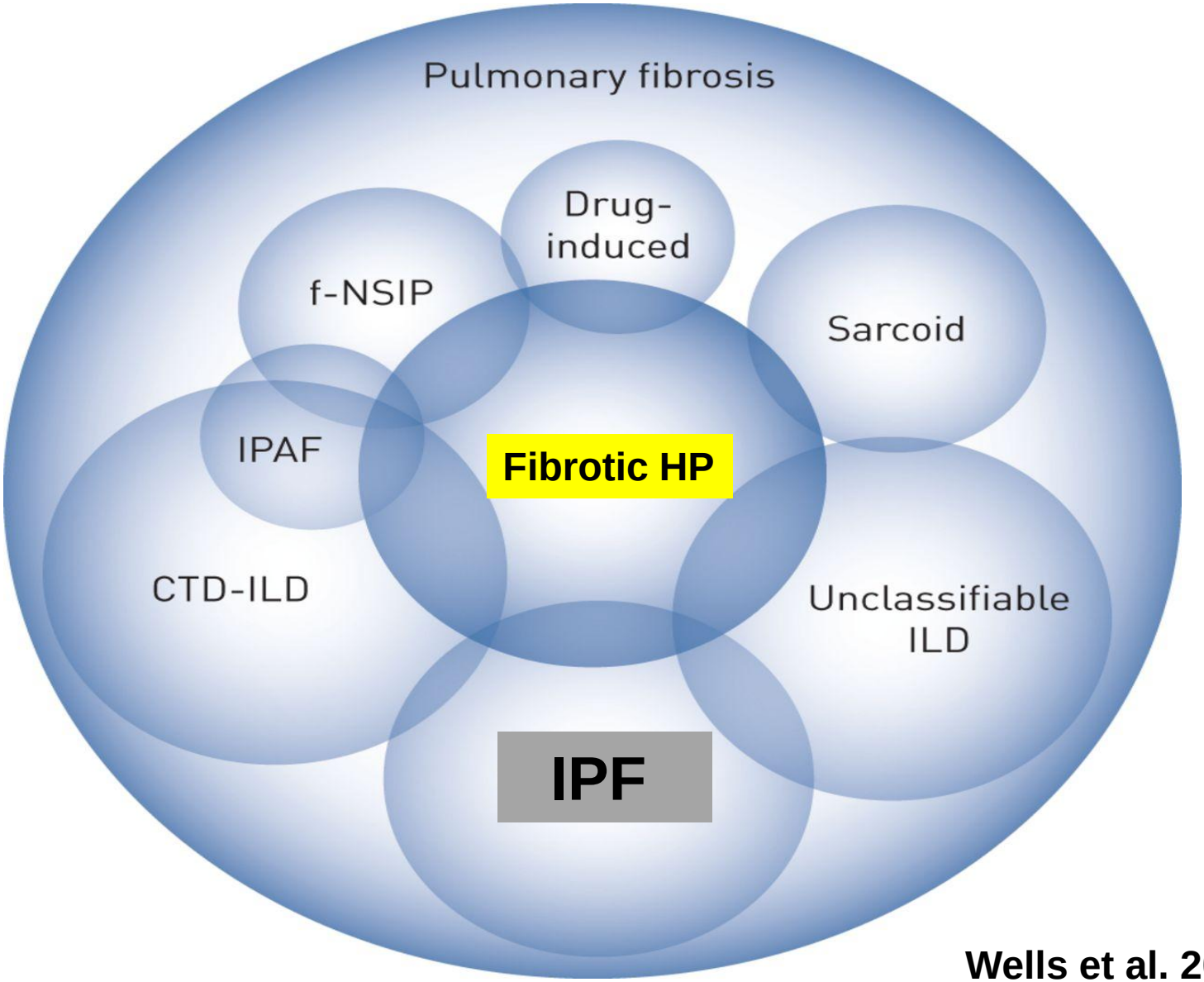


Wells et al. 2018

# Inter-MDT agreement in the setting of diffuse lung disease

**IPF Kappa=060**

**Hypersensitivity pneumonitis**

**Kappa = 0.24**

*<0.4 = poor,*

*0.4-0.6 = satisfactory,*

*0.6-0.8 = good,*

*>0.8 = excellent*

Walsh SL et al, Lancet Resp Med 2016: in press

# HP ΚΑΙ ΣΥΝΟΣΗΡΟΤΗΤΕΣ

**Fig. 17**—44-year-old man with chronic hypersensitivity pneumonitis (farmer's lung). High-resolution CT image shows bilateral ground-glass opacities and centrilobular emphysema. Patient was lifelong nonsmoker. (Courtesy of Dr. Yvon Cormier, Quebec, Canada)

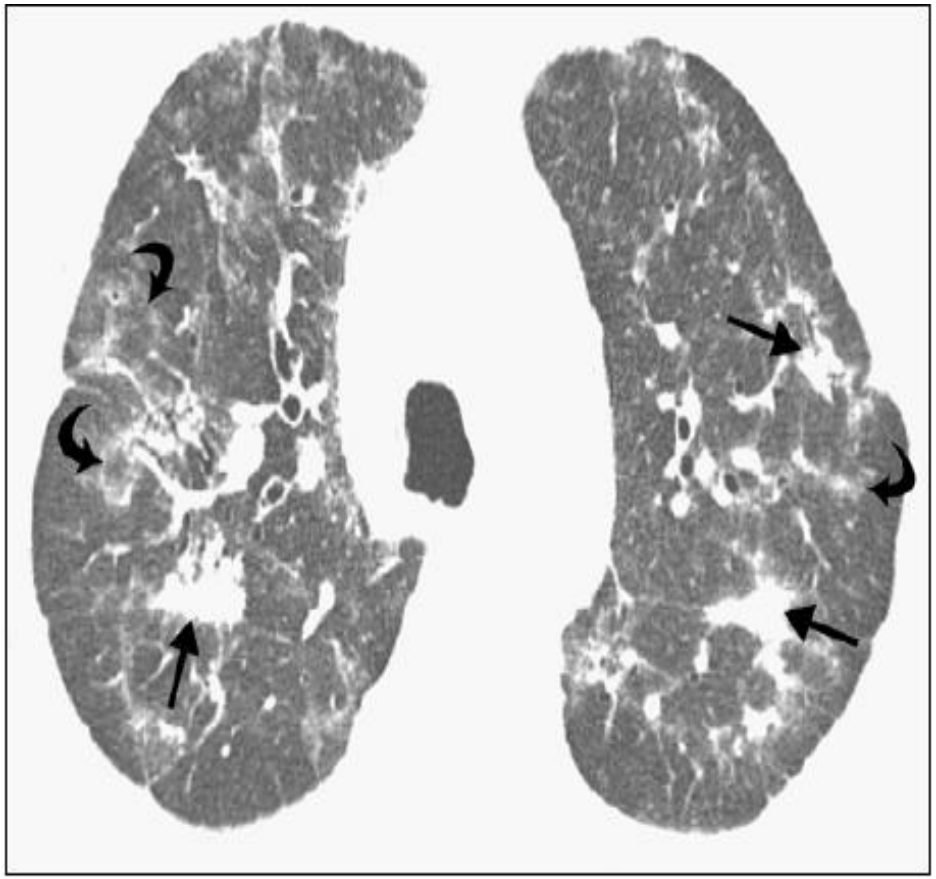

**HP and organizing pneumonia.**
**Courtesy of Silva I, et al.**

# BRONCHOALVEOLR LAVAGE IN HP

- Αυξημένος αριθμός (ολικός και %) λεμφοκυττάρων, T cells, mast cells.
- Και σε ασυμπτωματικούς ασθενείς.
- Φυσιολογικός αριθμός λεμφοκυττάρων αποκλείει την HP, εκτός από υπολειμματική νόσο.
- CD4:CD8 -ΔΕΝ ΣΥΝΙΣΤΑΤΑΙ!.

  *[Range according to the type of causative antigen, the clinical status, smoking habit, etc].*
- Οξεία προσβολή = αυξημένος αριθμός ουδετεροφίλων και λεμφοκυττάρων.

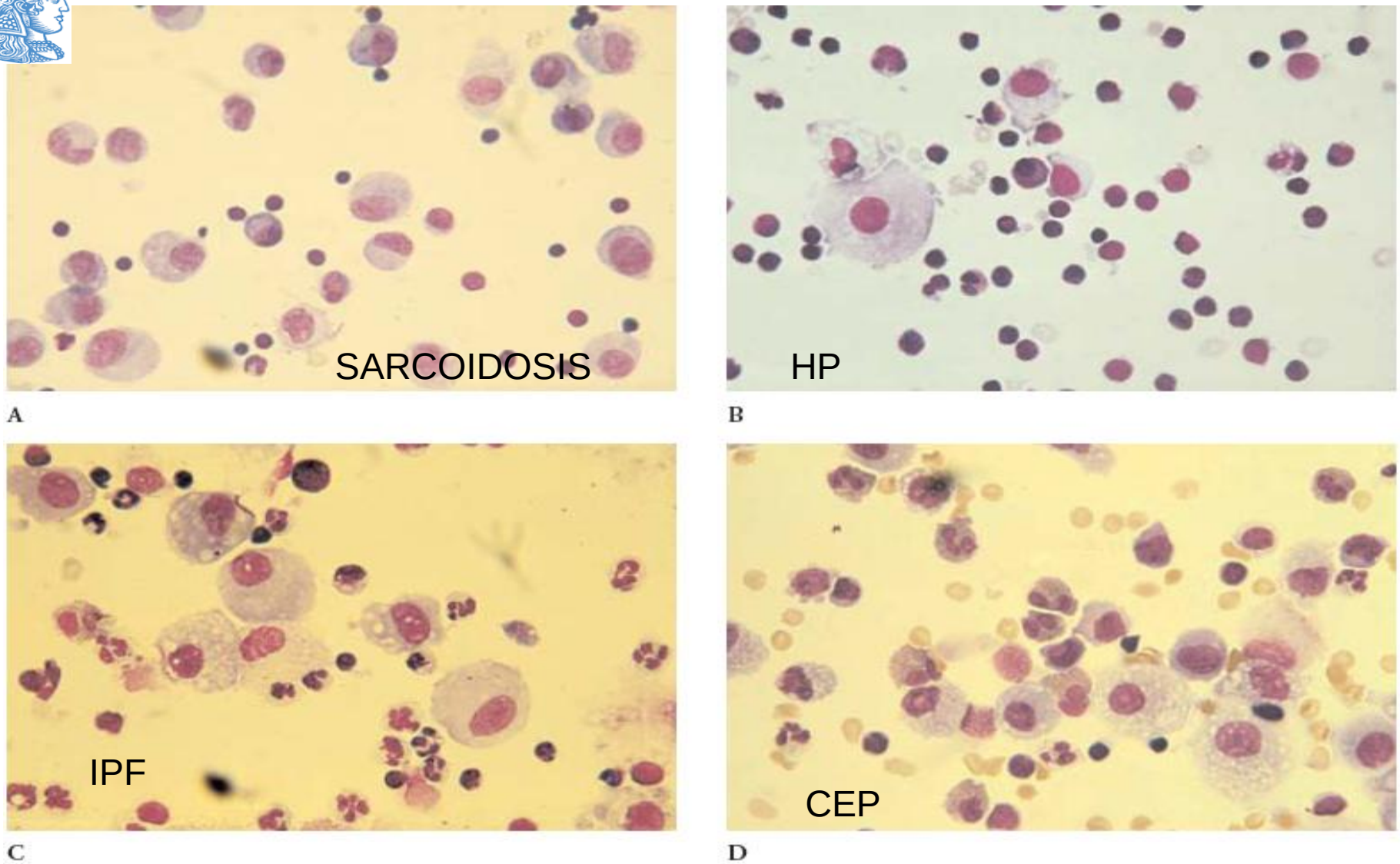


**Figure 5–8** Representative BAL cellular patterns of interstitial lung disease. MGG ×400. *A,* Lymphocytic alveolitis of sarcoidosis. Monomorphous appearance of macrophages. *B,* Lymphocytic alveolitis of hypersensitive pneumonitis. Striking predominance of lymphocytes, many of them being activated. Foamy macrophages and heterogeneous size of macrophages. *C,* Neutrophilic alveolitis of IPF. *D,* Eosinophilic alveolitis of chronic eosinophilic pneumonia.

EUROPEAN RESPIRATORY *journal*

# Diagnostic value of BAL lymphocytosis in patients with indeterminate for UIP imaging pattern

*Eur Respir J* 2019;

Vasilios Tzilas, Argyrios Tzouvelekis, Evangelos Bouros, Thodoris Karampitsakos, Maria Ntasiou, Mattheos Katsaras, Ulrich Costabel, Athol Wells, Demosthenes Bouros

## Diagnostic value of BALF

Reevaluation of patients driven by BALF results, led to a change in diagnosis in 14 patients (14.7%). In the majority of these cases (11/14, 78.6%) the initial diagnosis was altered from IPF to HP. In the remaining cases, the initial diagnosis was changed from Unclassifiable fibrosis to HP, from IPF to and from NSIP to HP. Interestingly, identification of a previously unidentified inciting agent occurred in seven patients.

# Βιοψία πνεύμονος.

- **Η βιοψία πνεύμονος βοηθά στην ορθή διάγνωση, στην εκτίμηση της δραστηριότητας, της προόδου της νόσου και στην απάντηση στη θεραπεία.**
- **Θεωρείται το *"αργυρό διαγνωστικό κριτήριο – silver standard"*.**
- **Δεν απαιτείται όταν τα υπάρχοντα κλινικά, ακτινολογικά, και εργαστηριακά δεδομένα είναι επαρκή για την διάγνωση.**

# 4 κύρια ιστολογικά χαρακτηριστικά

1. **Διήθηση διαμέσου ιστού από μονοπύρηνα**
2. **Μικρά, ασαφή <u>μη νεκρωτικά κοκκιώματα</u> *(non caseating granulomas)*- απουσία στο ~1/3 των περιπτώσεων.**
3. **Βρογχιολίτιδα, συχνά παρόμοια με την αποφρακτική (ΒΟ), *<u>περιβρογχιολικά</u>, λεμφοκυτταρική.***
4. **Διάμεση ίνωση/ ομοία με την UIP.**

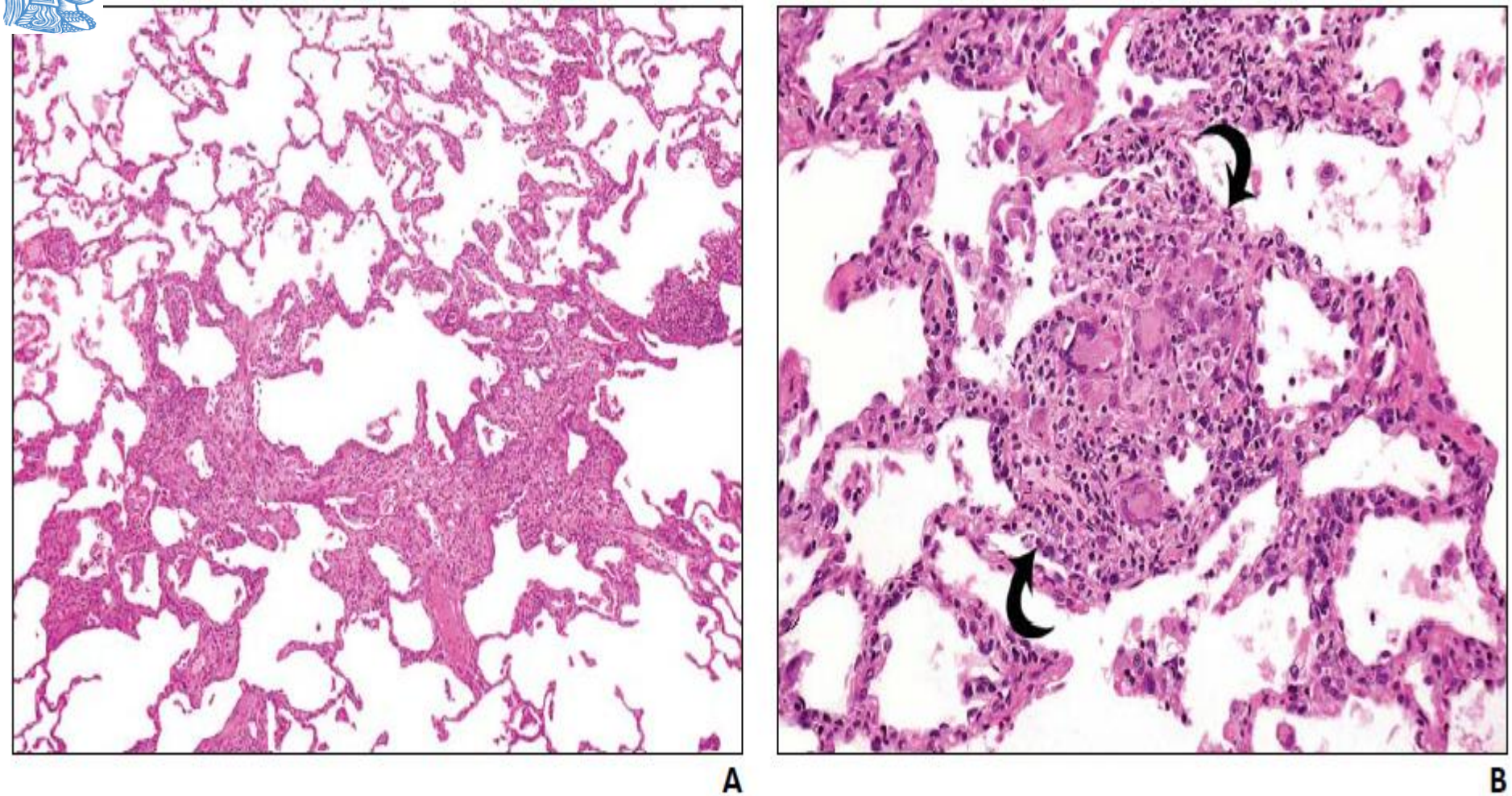


**Fig. 1**—35-year-old woman with subacute hypersensitivity pneumonitis (bird fancier's lung).

**A**, Photomicrograph of histopathologic specimen obtained at surgical lung biopsy shows moderate, diffuse, bronchiolocentric chronic lymphocytic inflammatory infiltrate. (H and E, ×60)

**B**, Magnified view of different area from **A** shows poorly formed granuloma (*arrows*) and chronic interstitial inflammatory infiltrate. (H and E, ×200)

*AJR* 2007; 188:334–344

# Ο ΡΟΛΟΣ ΤΩΝ ΙΖΗΜΑΤΙΝΩΝ ΚΑΙ ΤΗΣ ΠΡΟΚΛΗΣΗΣ

- **Πρέπει να διενεργούνται (serum IgG ab) σε έκθεση σε γνωστό αντιγόνο.**
- **Ψευδώς αρνητικές σε χρόνιες περιπτώσεις.**
- **Η παρουσία τους σημαίνει έκθεση και ανοσολογική απάντηση**

***(μέχρι 50% σε ασυμπτωματικούς pigeon breeders and 2–10% σε ασυμπτωματικούς αγρότες).***

- **Πρόκληση με εισπνεόμενο αντιγόνο- μόνο σε ειδικά κέντρα.**

# ΔΙΑΚΡΙΣΗ HP ΑΠΟ ΑΛΛΕΣ ΔΠ

- **Συχνά συγχέονται με άλλες διάμεσες πνευμονοπάθειες και *αντίθετα*, εκτός αν είναι εμφανής η έκθεση!**

- **> 30% δεν έχουν αναγνωρίσιμη έκθεση!**

- ***(AJRCCM 188,2013)***

# ΧΑΡΑΚΤΗΡΙΣΤΙΚΑ IPF ΚΑΙ ΙΝΩΤΙΚΗΣ HP

| Features | Fibrotic HP | IPF |
|---|---|---|
| *Demographics* | | |
| Sex | No difference | More frequent in men |
| Smoking | Protective | Risk factor |
| Age | No predilection | More frequent > 55 years |
| *Clinical symptoms/history* | | |
| Clubbing | Often | Often |
| Squeaks | Typical | Absent |
| Bibasal crackles | Frequent | Frequent |
| Systemic disease features (fever, joint pains, fatigue) | Often | Absent |
| Exposure to antigens | Frequent | Rare |
| Positive precipitins | Frequent | Rare |

# HRCT ΣΕ IPF ΚΑΙ ΙΝΩΤΙΚΗ HP

| *Imaging (CT)* | HP | IPF |
|---|---|---|
| Distribution | Upper lobe predominance | Peripheral, predominantly basal |
| Mosaic attenuation | Frequent | Absent/Limited |
| Nodules | Frequent | Absent |
| Interlobular septal thickening | Often | Absent/Limited |
| Honeycombing | Often | Frequent (typical for UIP pattern) |
| Bronchocentricity | Frequent | Absent |
| Discrete cysts | Often | Absent |
| Consolidation | Rare | Absent |

# ΜΙΚΡΟΣΚΟΠΙΚΑ ΕΥΡΗΜΑΤΑ ΣΕ IPF ΚΑΙ HP

| | HP | IPF |
|---|---|---|
| *Bronchoalveolar lavage (BAL)* ★ | Lymphocytosis > 25–30% | Lymphocytosis < 20% |
| *Histological* | | |
| Fibroblast foci | Often | Frequent |
| Granulomas/giant cells/Schaumann bodies | Frequent | Rare |
| Organizing pneumonia | Rare | Rare |
| Honeycombing | Often | Frequent |
| Paraseptal subpleural distribution | Often | Frequent |
| Bronchocentricity | Frequent | Absent |

# Putting it all Together

- Physiology
  - Full PFTs
- Gas exchange
  - 6MWT
- Radiology
  - HRCT
- History
- Exam
- Labs
  - ANA, RF, anti-CCP
- Pathology

→ Summary Diagnosis

# ΘΕΡΑΠΕΙΑ HP

- **Αποφυγή του αντιγόνου**
  - **Πολύ σημαντική**
  - **συνήθως η πάθηση υποχωρεί**
  - **Αποφυγή ευαισθητοποίησης άλλων ατόμων**
  - **Δεν είναι πάντα δυνατή / αποτελεσματική**
  - **Το αντιγόνο των πτηνών μπορεί να παραμένει και 6 μήνες στο σπίτι μετά την απομάκρυνση των πτηνών *(βιολογικός καθαρισμός).***

# TREATMENT OF HP

## Κορτικοειδή – AZA- MMF

- Επιταχύνει την αρχική αποδρομή σε βαριά ασθενείς
- Έναρξη 20 mg/d (< 60 mg/d), συντήρηση
- 10-15 mg/d
- Η μακροχρόνια πορεία δεν αλλάζει..
- Early transition to MMF or azathioprine may be an appropriate therapeutic approach in cHP.
- *Thiopurine methyltransferase enzyme activity [AZA]*

# TREATMENT OF HP

## Antifibrotics in chronic HP?

- Pirfenidone
- Nintedanib [*INBUILT Trial. NEJM 2019]*

## LUNG TRANSPLANTATION…

**Table 1.** Treatment Strategies in Hypersensitivity Pneumonia

| Inflammatory Features* Present |
| --- |
| • Environmental evaluation and antigen remediation |
| • Consider a trial of immunosuppression. Watchful waiting is also an option in stable and/or mild disease, or if an antigen is identified and removed |
| • Suggested immunosuppressive regimen[†]: |
| 1. Corticosteroids (0.5–1 mg/kg daily prednisone equivalent) ± cytotoxic agent[‡§] |
| a. Taper prednisone to 20 mg daily in the first 3 mo |
| b. Close interval monitoring of $FEV_1$, FVC, and $DL_{CO}$ (consider every 1–2 mo initially) |
| 2. Taper corticosteroid to <20 mg daily when pulmonary function plateaus (presuming initial improvement) |
| a. Interval pulmonary function every 3–4 mo. Consider HRCT at 3–6 mo |
| b. If disease worsens during steroid taper, consider cytotoxic agent (if not already initiated). Evaluate for infection or reintroduction of antigen, as indicated |

# Ο ΟΡΙΣΜΟΣ ΤΟΥ ‘ΕΜΠΕΙΡΟΓΝΩΜΟΝΑ’

**A person who is very knowledgeable about or skillful in a particular area.**

Cambridge Dictionary

‘An expert is a man who has stopped thinking - he knows!’
Frank Lloyd Wright

‘An expert is somebody who is more than 50 miles from home, has no responsibility for implementing the advice he gives, and shows slides’
Edwin Meese III

# ΠΡΟΓΝΩΣΤΙΚΟΙ ΠΑΡΑΓΟΝΤΕΣ HP

1. Η διάρκεια και η ένταση της έκθεσης
2. Οι ιστολογικές βλάβες (OP, cellular NSIP vs. fibrotic NSIP or a UIP-like pattern)
3. Η παρουσίαση (acute, subacute, or chronic HP)
4. Η πληκτροδακτυλία (χειρότερη πρόγνωση)
5. Οι ηλικιωμένοι είναι λιγότερο πιθανό να βελτιωθούν.
6. Ούτε οι PFTs ούτε η CXR κατά την διάγνωση δεν σχετίζονται με την πρόγνωση.
7. Τα HRCT πρότυπα μπορεί να είναι προγνωστικά της χρονίας HP.

# Pathologic Findings and Prognosis in a Large Prospective Cohort of Chronic Hypersensitivity Pneumonitis

*Ping Wang, MD; Kirk D. Jones, MD; Anatoly Urisman, MD; Brett M. Elicker, MD; Thomas Urbania, MD; Kerri A. Johannson, MD; Deborah Assayag, MD; Joyce Lee, MD; Paul J. Wolters, MD; Harold R. Collard, MD; and Laura L. Koth, MD*

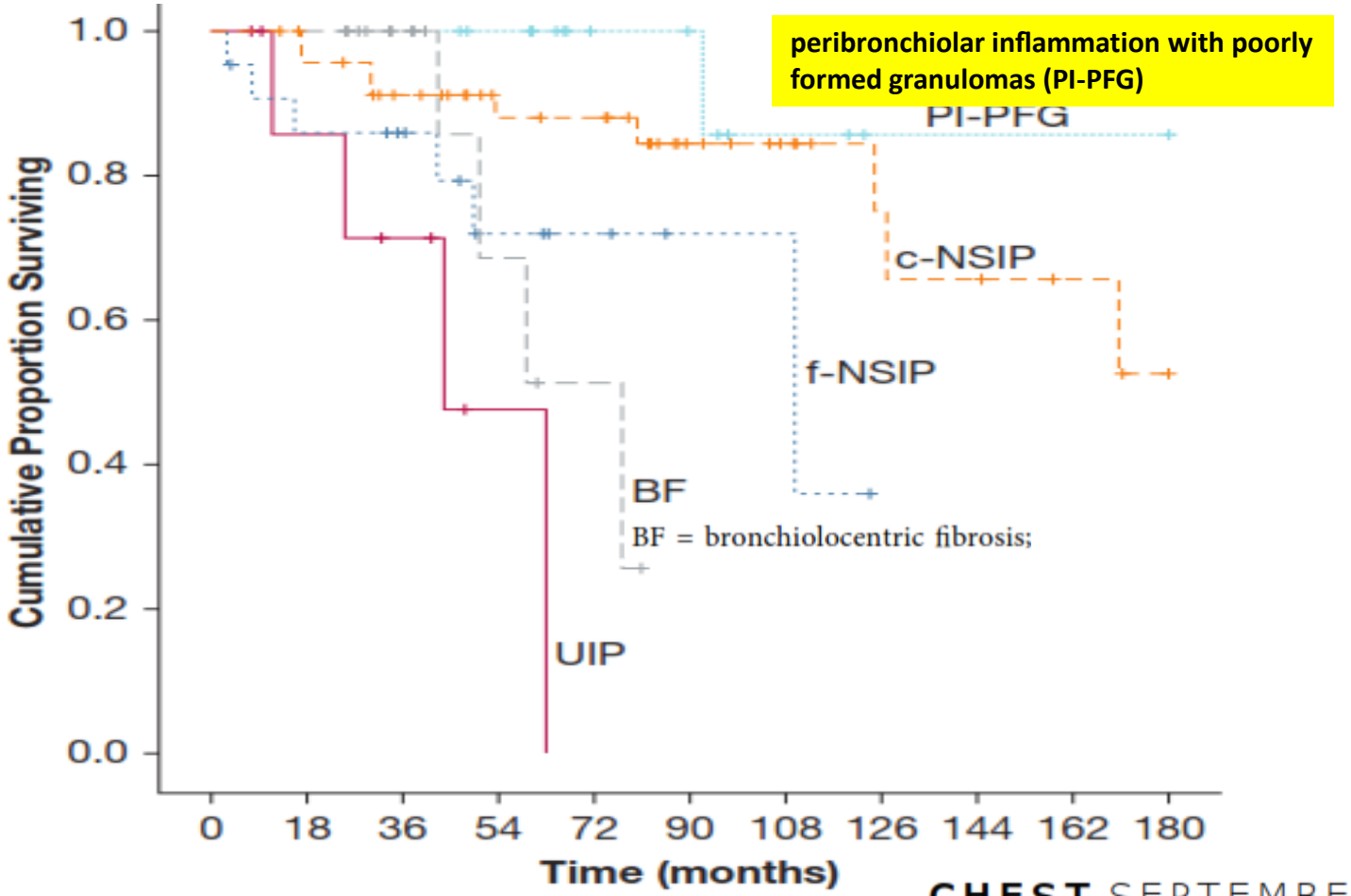


CHEST SEPTEMBER 2017

# Pathologic Findings and Prognosis in a Large Prospective Cohort of Chronic Hypersensitivity Pneumonitis

CHEST SEPTEMBER 2017

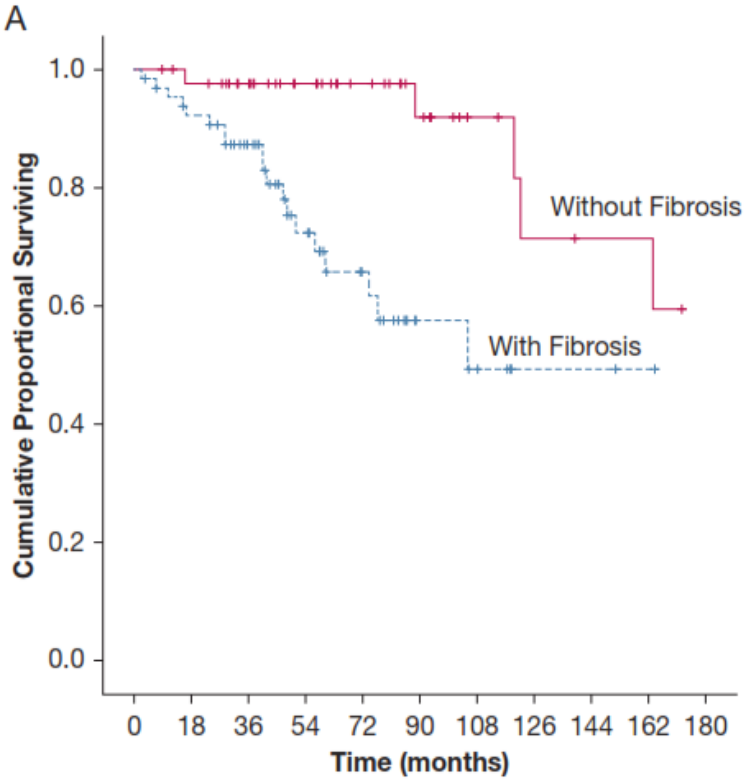


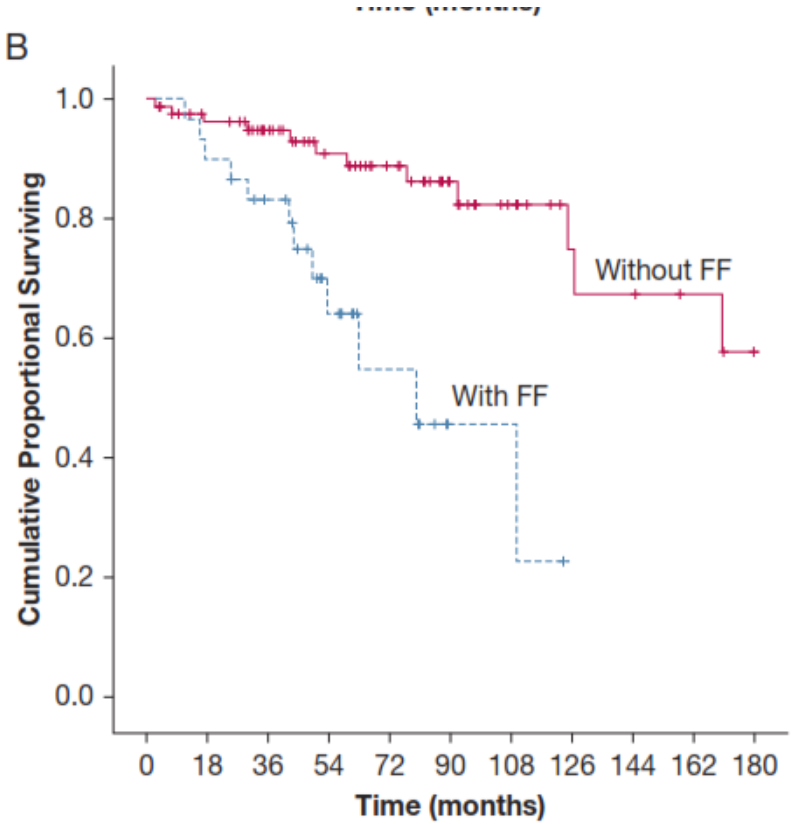


**FF=Fibroblastic foci**

# ΜΕΣΗ ΕΠΙΒΙΩΣΗ= 7 years!

**TABLE 1** ] Selected Studies Reporting Median Survival in Chronic HP According to Pathologic Pattern

| Series | Pathologic Pattern/Median Survival | | | Comments |
|---|---|---|---|---|
| | UIP | Fibrotic NSIP | Centrilobular Fibrosis Only | |
| Ohtani et al[3] | 50 mo | 50 mo | | • Bird exposures |
| Churg et al[2] | 36 mo | 36 mo | 144 mo | • Mixed exposures |
| Gaxiola et al[4] | 40 mo | | | • Bird exposures |
| Takemura et al[5] | 80% survival at 100 mo | | | • Mixed exposures<br>• UIP comparison group; median survival, 100 mo |
| Chiba et al[6] | 27 mo if > 2.2 fibroblast foci/cm$^2$<br>70% survival at 100 mo if < 2.2 fibroblast foci/cm$^2$ | | | • Bird exposures<br>• Amounts of HRCT reticulation, honeycombing, traction bronchiectasis higher in cases with > 2.2 fibroblast foci/cm$^2$ |
| Wang et al[1] | 40 mo | 108 mo | 60 mo | • Mixed exposures |

# COMPLETE RESOLUTION

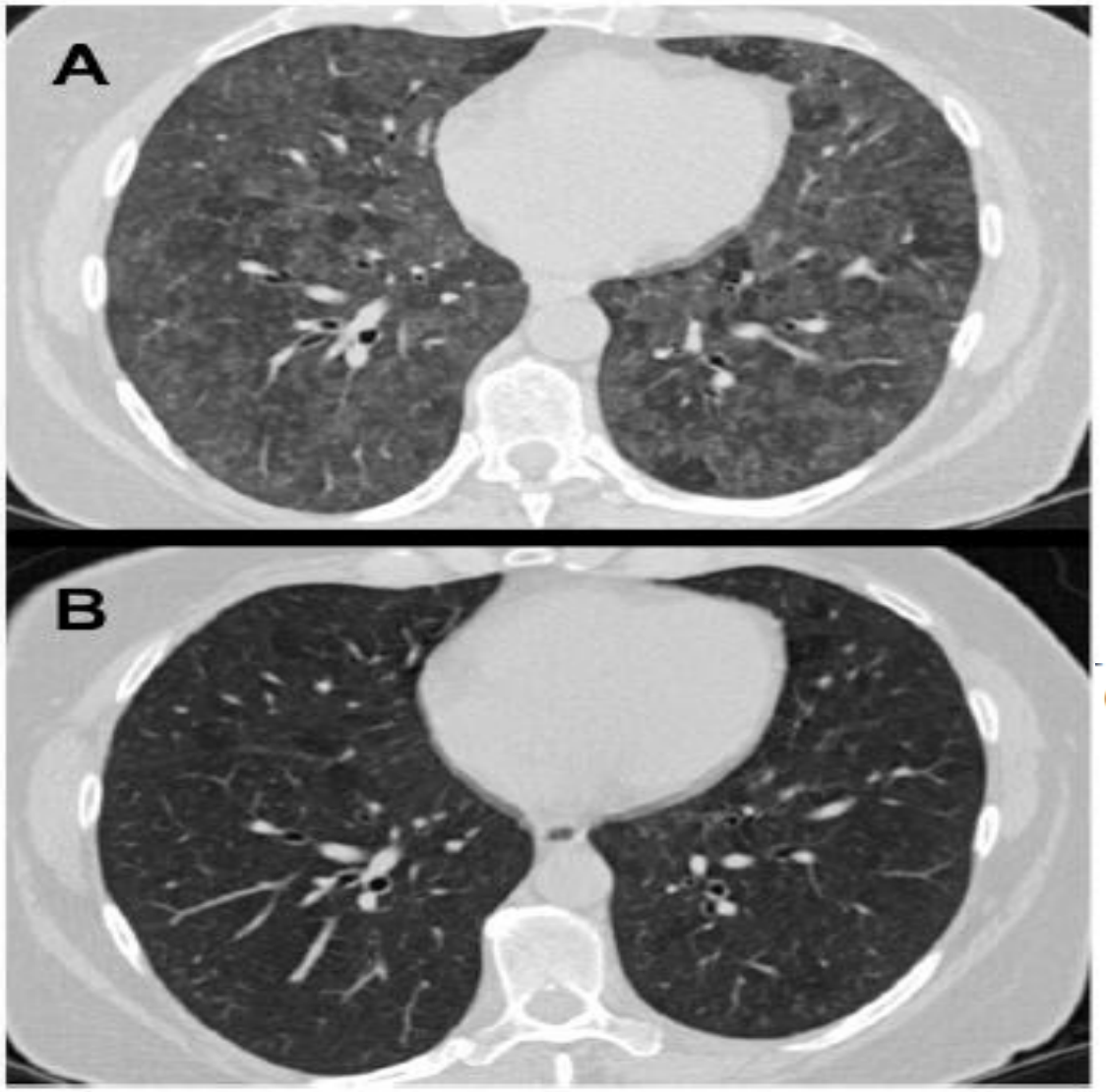


*CHEST 2012; 142(1):208–217*

FIGURE 1. A, High-resolution CT scan of a patient with hot tub lung: patchy bilateral ground-glass opacities with poorly defined small centrilobular nodules. B, Same patient, 6 weeks following exposure withdrawal, showing full radiologic recovery.

# PROGRESS TO FIBROSIS

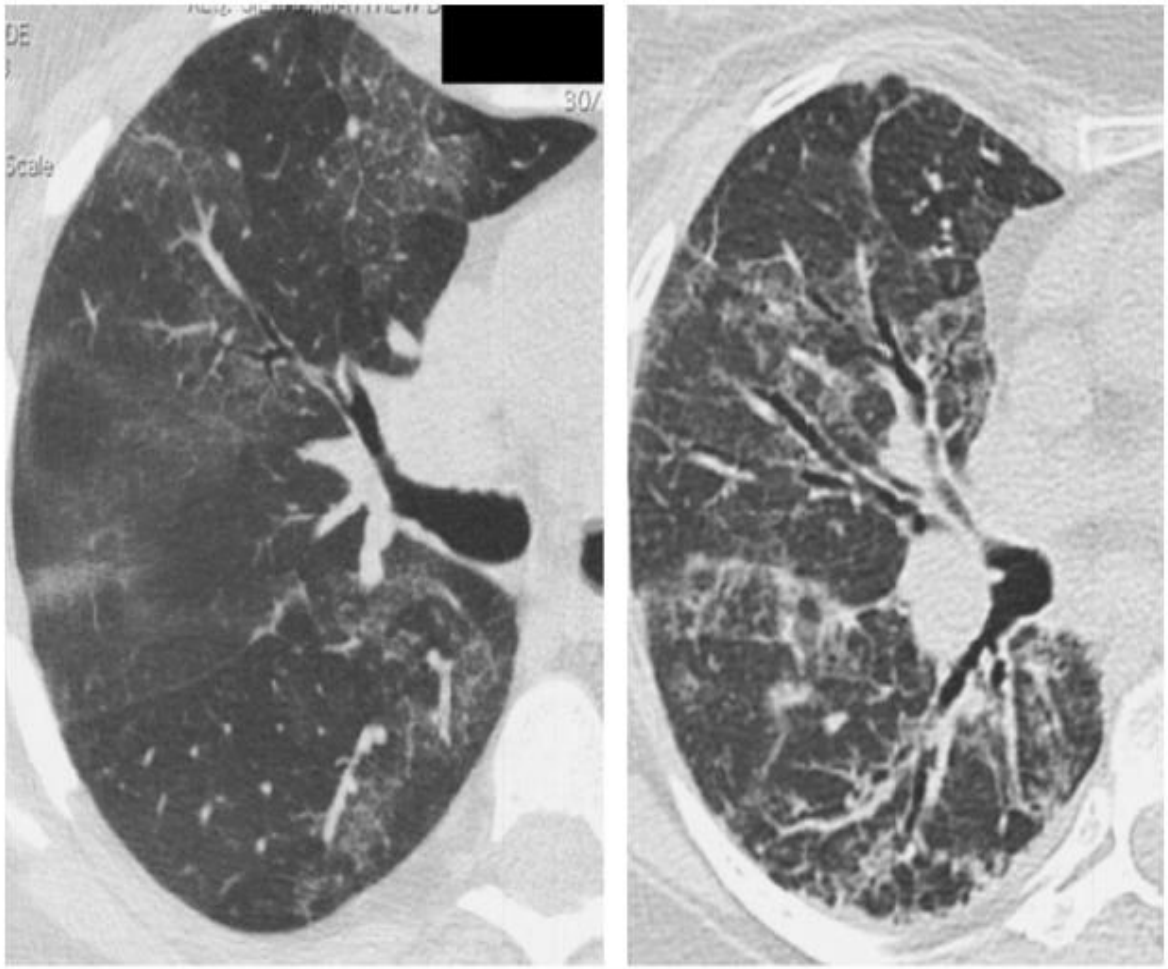

**Figure 13.** Progression of insidious hypersensitivity pneumonitis to fibrosis. **(a)** Axial high-resolution CT image of the right lung at the takeoff of the right middle lobe bronchus shows patchy ground-glass opacity. **(b)** Axial high-resolution CT image obtained at a similar level 3 years later demonstrates a predominantly reticular abnormality with associated traction bronchiectasis, findings suggestive of fibrosis.

# The Course o HP is Variable

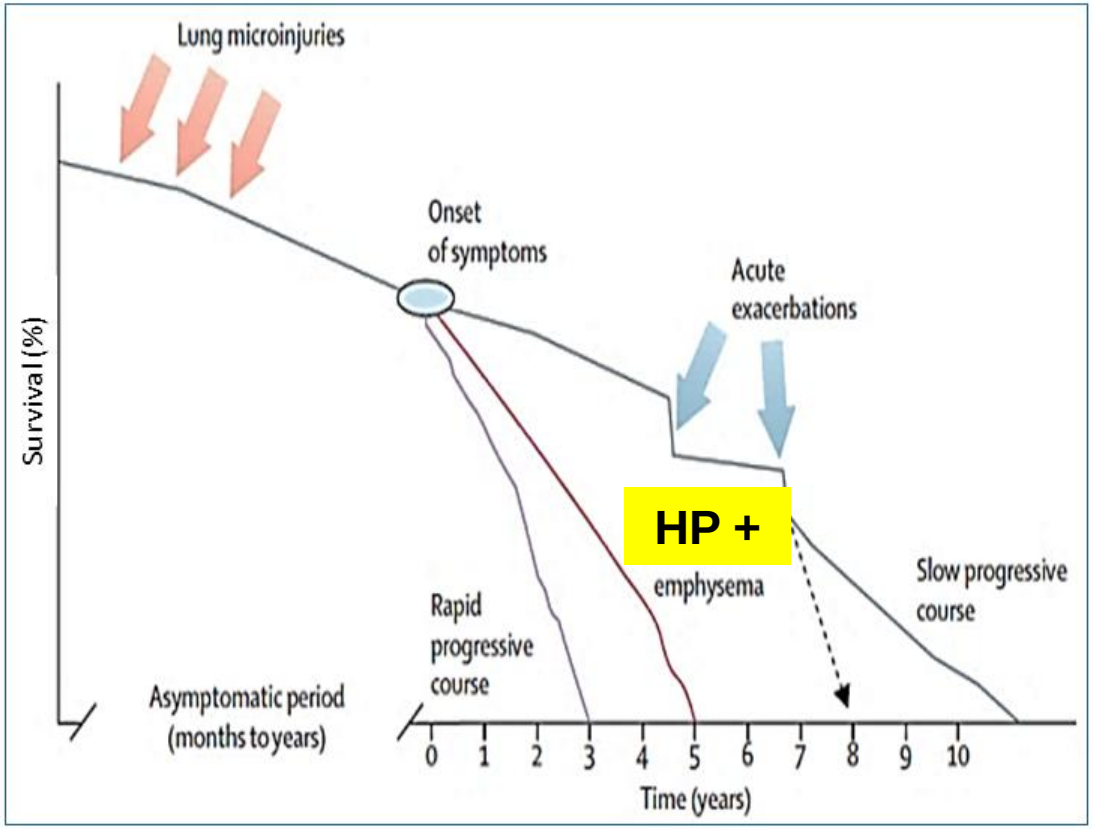


King TE Jr. et al. *Lancet*. 2011;378(9807):1949-1961.

# ACUTE EXACERBATIONS OF HP

**Seems to occur mainly in:**

- ***male smokers***
- ***BALF: fewer lymphocytes and increased neutrophils***
- ***with advanced fibrosis on HRCT***
- ***worse pulmonary* function**
- **Low survival**

**Pathology: DAD+OP**

# ΠΑΡΟΞΥΝΣΗ HP ΜΕΤΑ ΑΠΟ 7 ΧΡΟΝΙΑ.

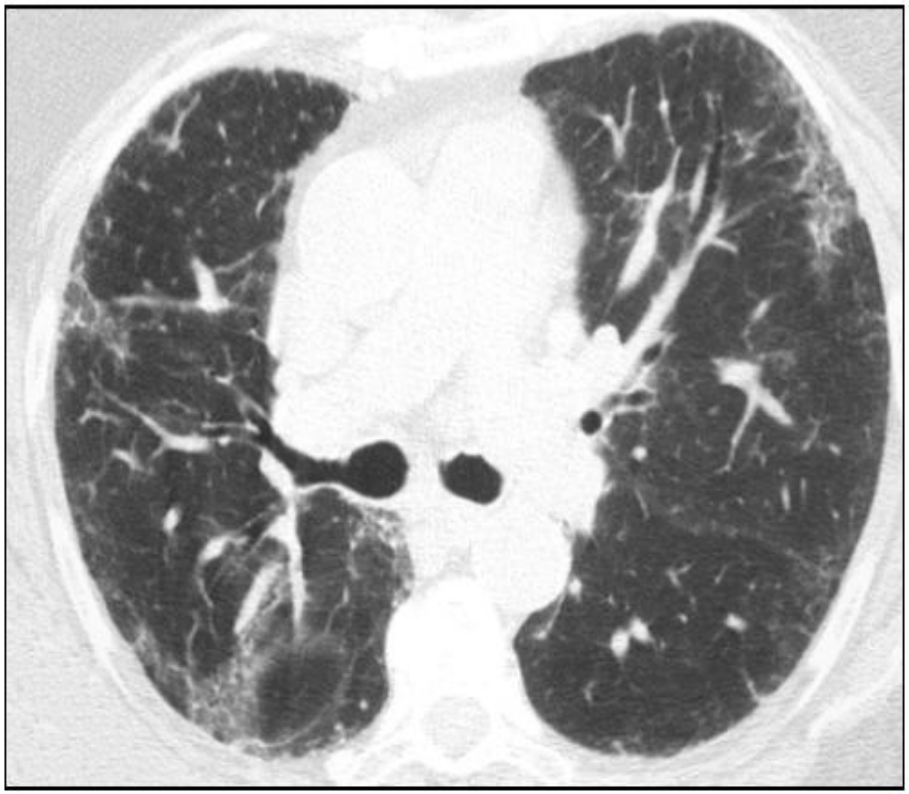

A

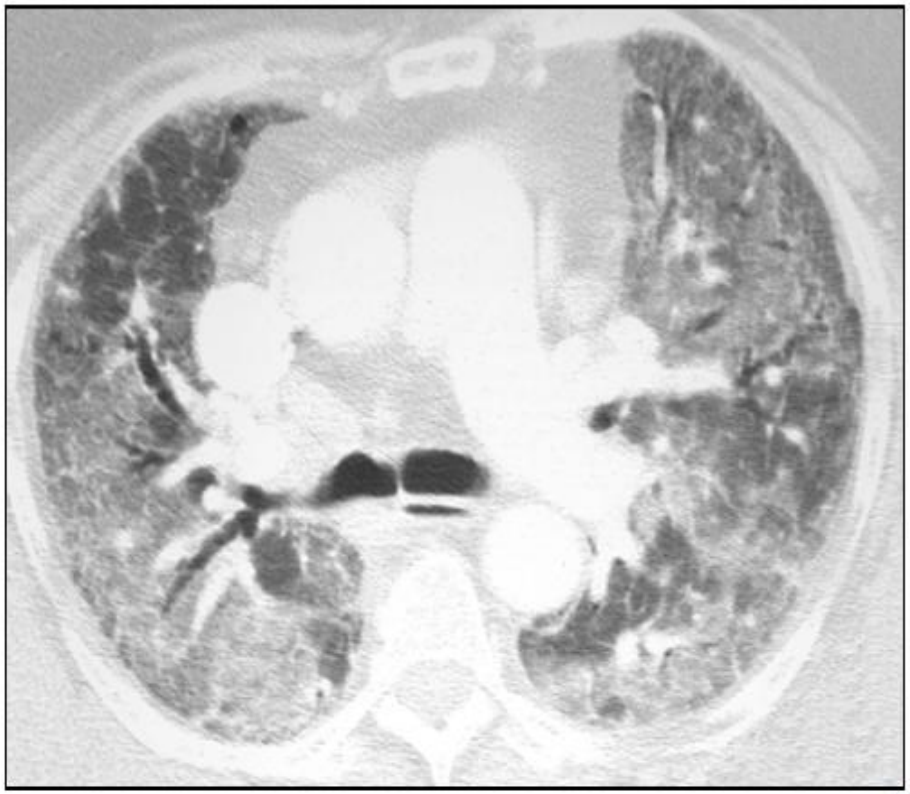

B

# DIAGNOSTIC ALGORITHM OF HP

Modified from: Selman M et al. AJRCCM 2012

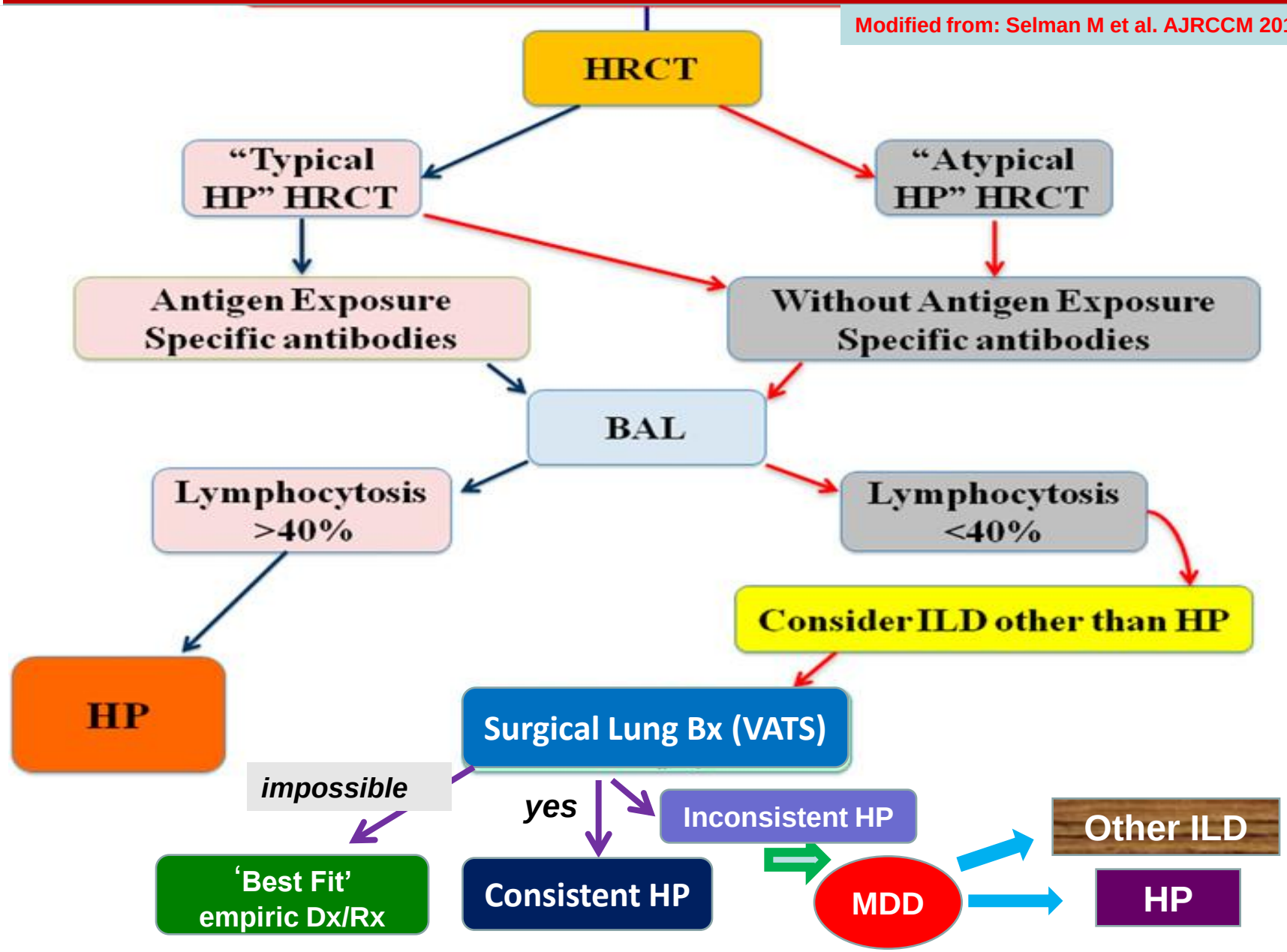

# Google University of Medicine

This certifies that Dr: _____ on recommendation of the faculty of the Google University of Medicine has conferred the degree of:

# Internet Doctor of Medicine

Who has honorably fulfilled all the requirements prescribed by the university for that degree.

President

Director

Date